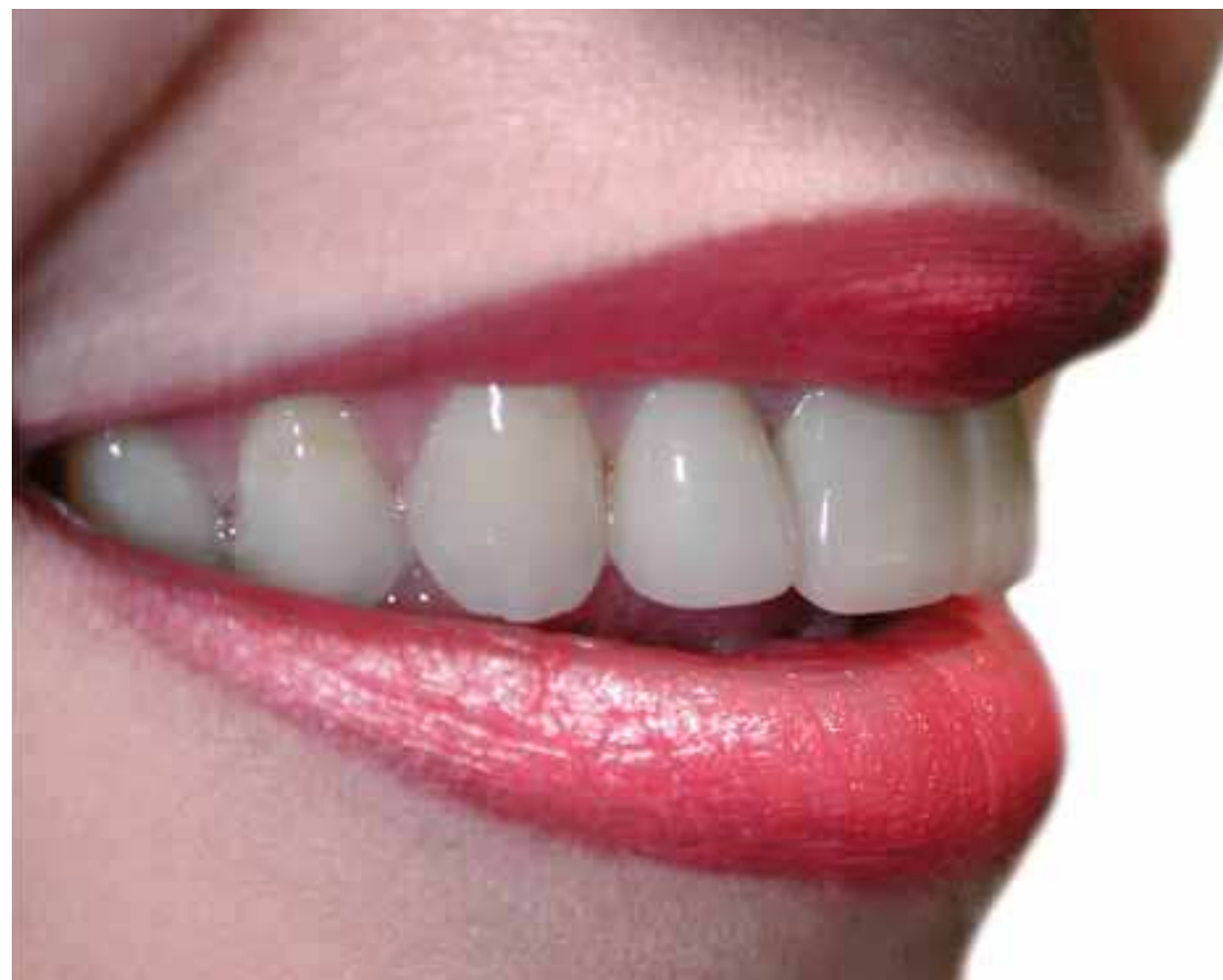

# Beautiful NobelEsthetics™ from Procera®



Beautiful NobelEsthetics™ from Procera®

**Nobel Biocare™**



[www.nobelbiocare.com](http://www.nobelbiocare.com)

17804 GB 0608. © Nobel Biocare Services AG, 2005.

Nobel Biocare, the Nobel Biocare logotype and all other trademarks used in this document are, if nothing else is stated or is evident from the context in a certain case, trademarks of the Nobel Biocare group.





A happy patient, looking ten years younger, and with lots of new-found energy.

Courtesy of Dr. Hans Åhlund & Ms. Bodel Sjöholm, Sweden

# It's time to give patients exactly what they want – beautiful teeth now™!

Esthetic dentistry is an idea whose day has come. With the enormous advances in implant dentistry, there has never been a more exciting time to be a dentist. More and more people now think of beautiful fully functioning teeth as their birthright – and our industry is at last in a position to deliver. Together, modern dental professionals and Nobel Biocare – the pioneering world leader of the field – can confidently answer this demand. We now have all the solutions we need for creating healthy happy patients.



## Table of Contents

Inge De Bruijn in 60 Seconds .....	6-7
Single tooth missing/Improving existing teeth.....	8-61
What Doctors are Saying.....	62-63
Several teeth or all teeth missing .....	64-83
The great leap forward.....	84-87



# Inge De Bruijn in 60 seconds

1. What are your greatest achievements in your swimming career?

Best Olympic athlete ever in The Netherlands  
4-Gold, 2-Silver, and 2-bronze Olympic medals  
3-times world champion world record holder

2. Do you do any other sports besides swimming?

Running, aerobics, Tae Bo®

3. What are your favorite recreation activities?

Shopping, going to the movies, going out for dinner, hanging out with friends

4. What's your favorite food?

Italian, especially my mom's lasagna

5. Which teeth did you fix?

The top six front teeth

6. Why did you choose Procera® for your treatment?

I was informed by friends about the good results from Procera® products.

7. Where you satisfied with the result?

Absolutely, lots of compliments since I've had it done. It makes me want to smile all day.

8. In what way is the smile an important asset for a star?

You are always in the public eye. And people pay attention to every little thing. So you have to be representative. And I love to smile.

9. What are your plans for the future?

I recently was a host of a travel TV program in China. It was amazing. And I hope to do some more of this. I'm ambassador of KiKa (children cancer free), busy doing a fitness DVD, and trying to get my own bikini and swimsuit label on the market.

10. What makes you smile?

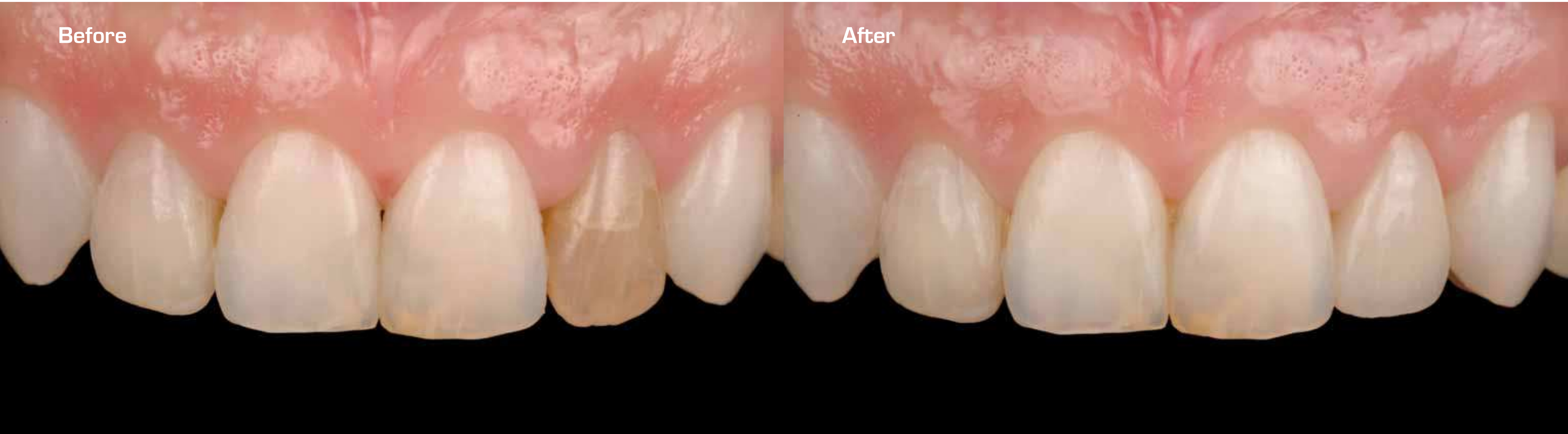Sunshine, friends and family, gold medals



Single tooth missing/improving existing teeth

Procera® Laminate  
Dr. Iñaki Gamborena, Spain

SINGLE TOOTH MISSING/  
IMPROVING EXISTING TEETH





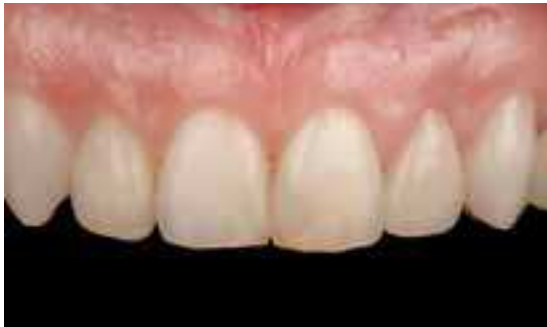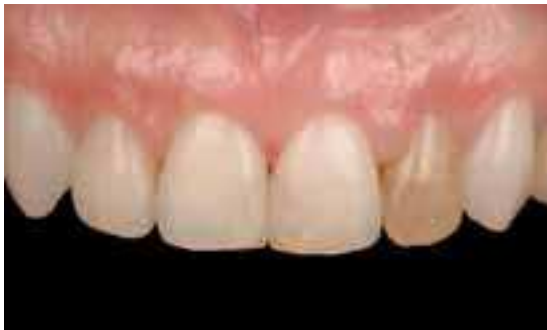# Procera® Laminate

Dr. Iñaki Gamborena, Spain

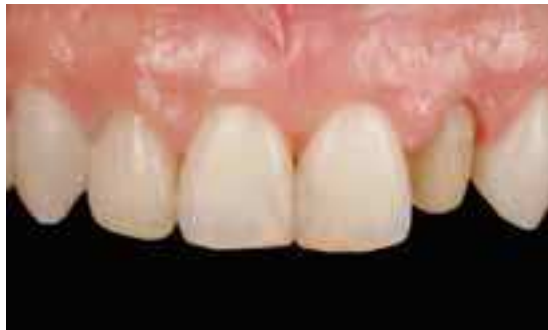Patient was aware of the dark discoloration of the left lateral incisor.

A previous internal bleaching was performed on that tooth without success. In order to optimize the esthetic outcome and achieve a long-lasting conservative treatment, a Procera® Laminate was chosen. The alumina coping creates a homogenous curtain effect and mask the dark discoloration present on the tooth.

Notice the excellent integration of the single Procera® Laminate with regard to the surrounding soft tissues and color.



SINGLE TOOTH MISSING/  
IMPROVING EXISTING TEETH



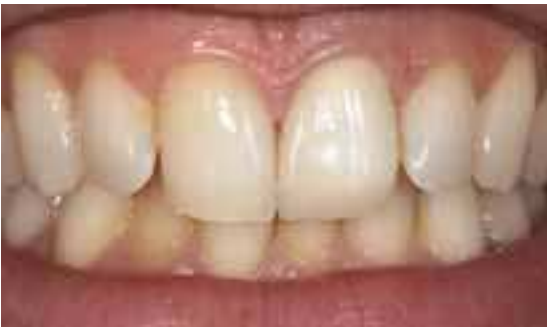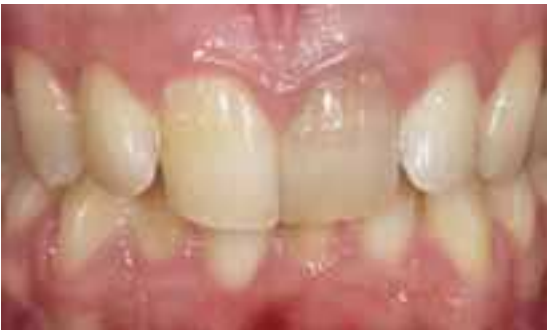# Procera® Laminate

Dr. Dario Adolfi, Brazil & Dr. Carlos Moura Guedes, Portugal

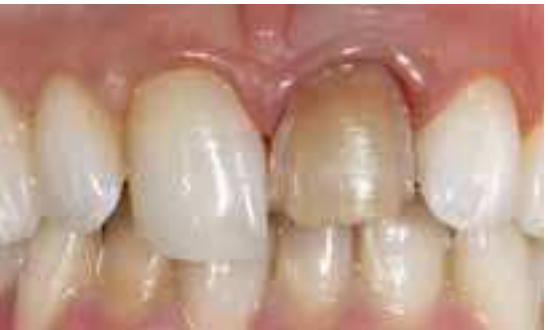Severe discoloration on upper left central, and different morphology compared with the upper right central.

Conservative preparation for laminate veneer and chamfer finish line.

Procera® Laminate after adhesive cementation with composite resin material.



SINGLE TOOTH MISSING/  
IMPROVING EXISTING TEETH

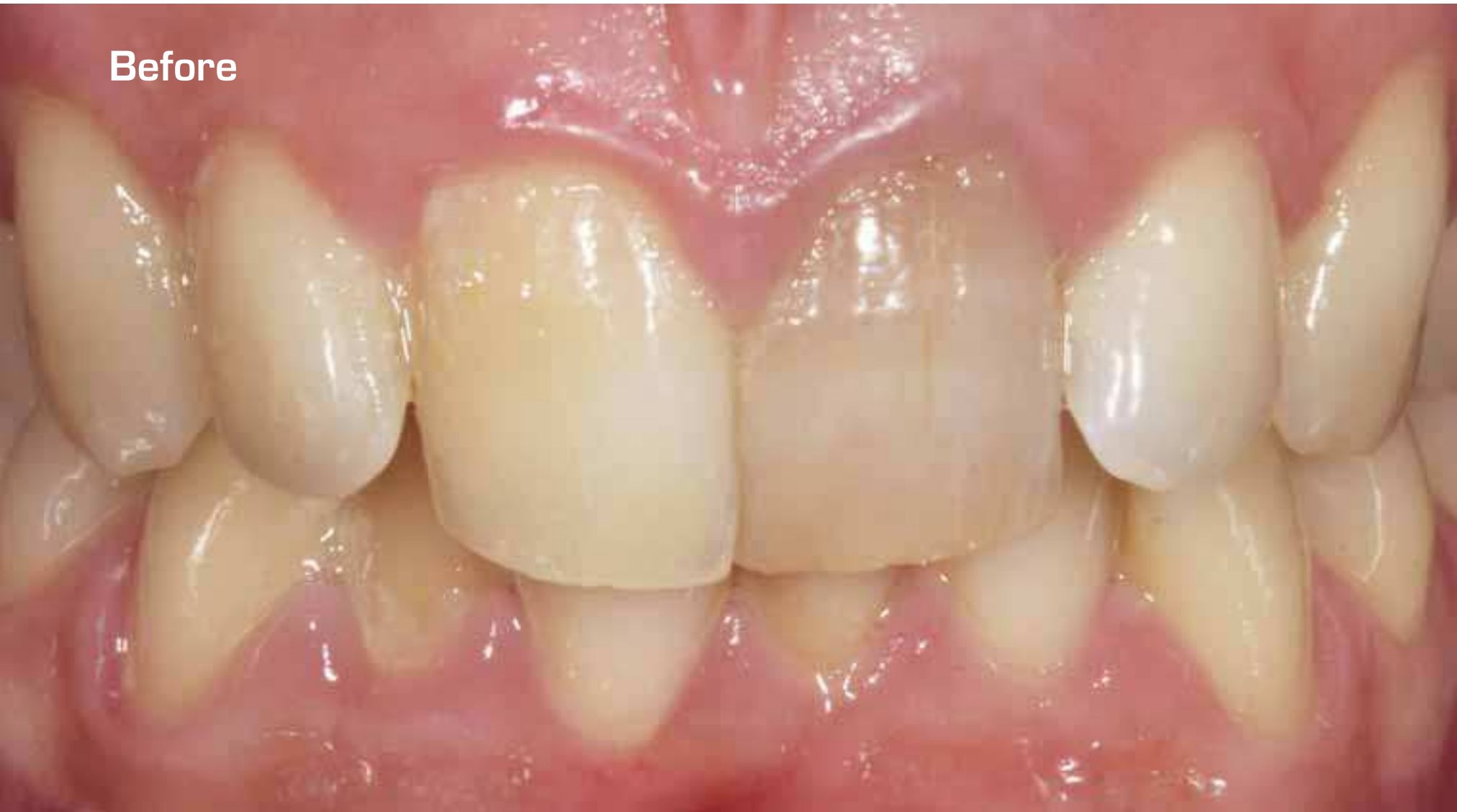

## Procera® Laminate

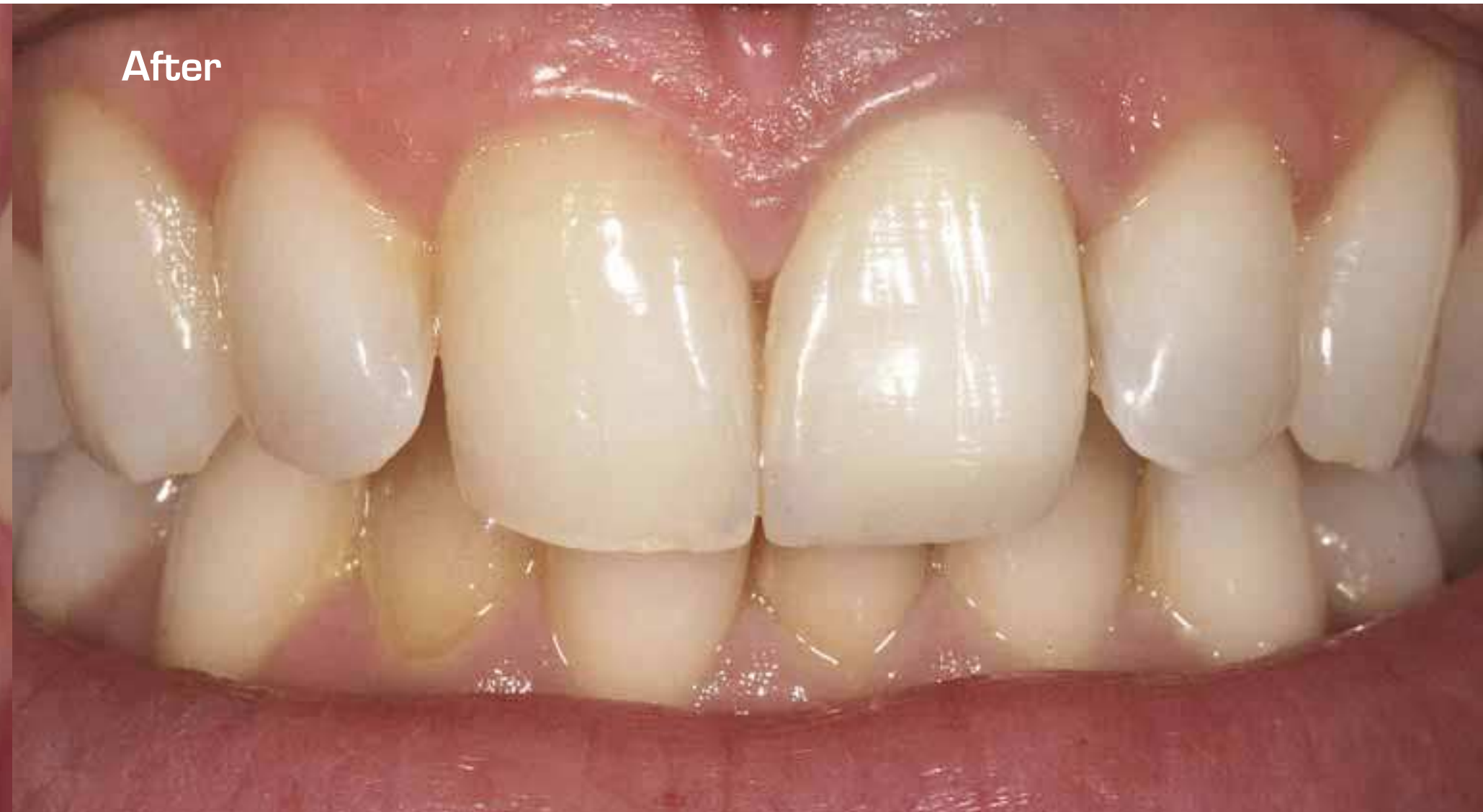Dr. Dario Adolfi, Brazil & Dr. Carlos Moura Guedes, Portugal

SINGLE TOOTH MISSING/  
IMPROVING EXISTING TEETH

Before



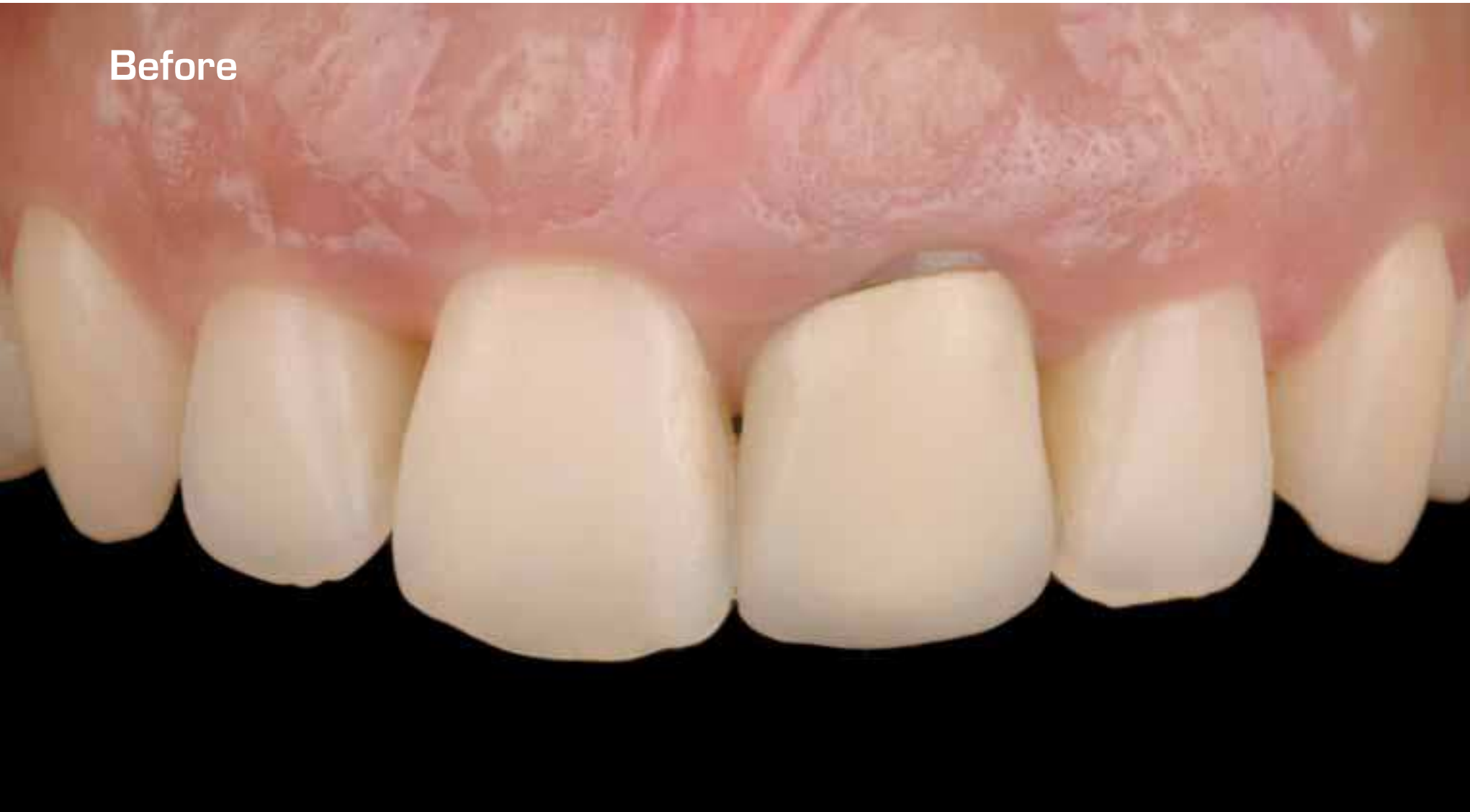After



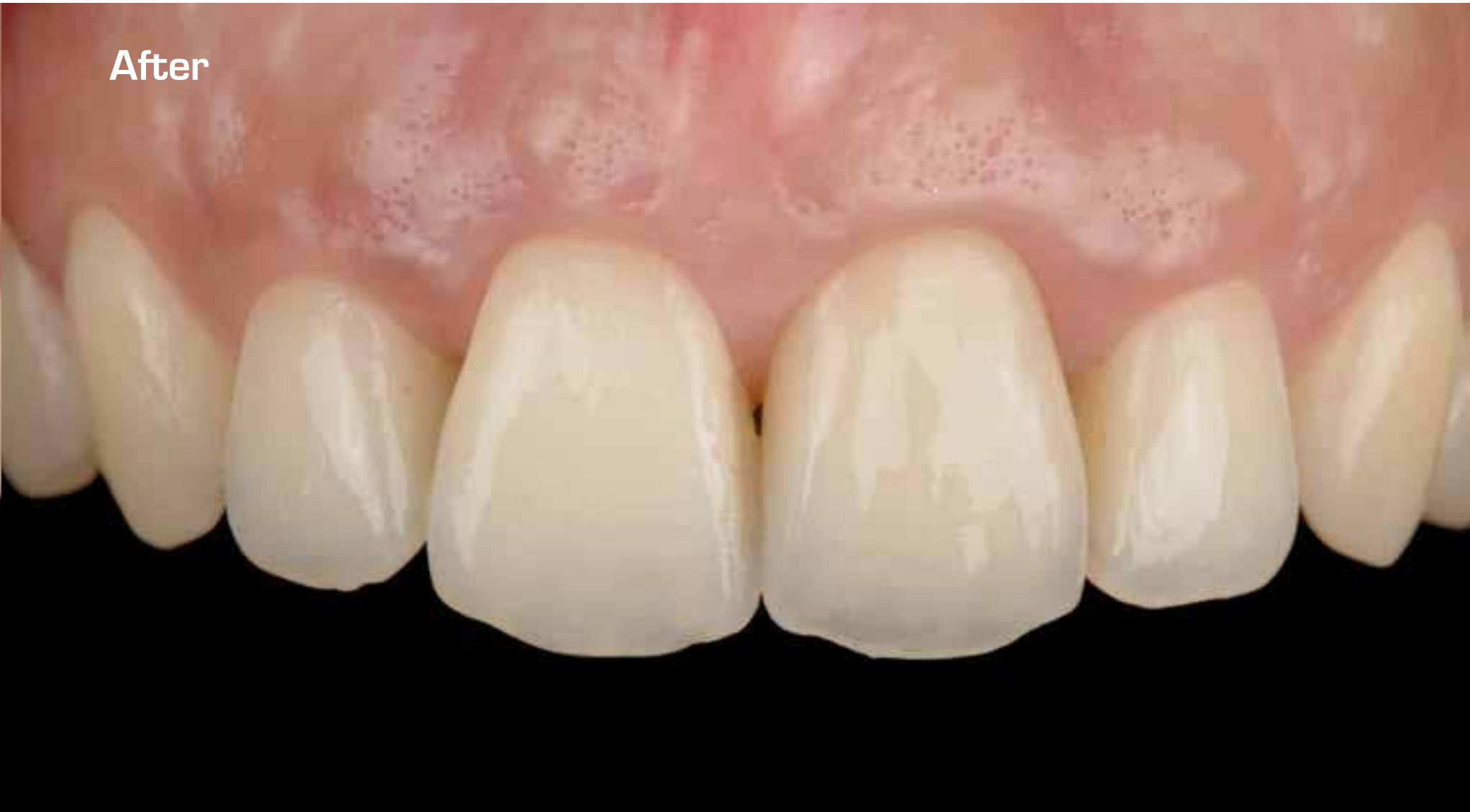SINGLE TOOTH MISSING/  
IMPROVING EXISTING TEETH



Before



After



## Procera® Crown Alumina

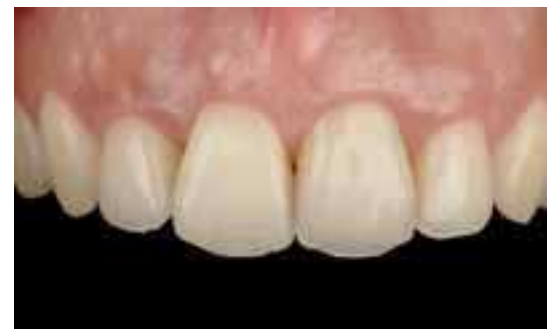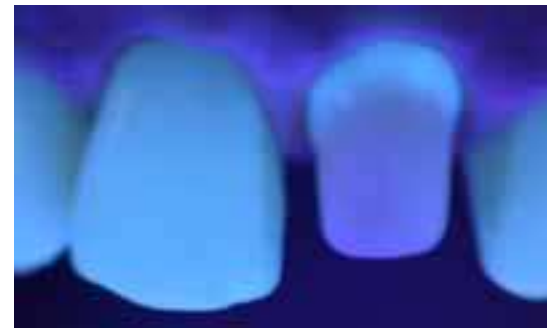
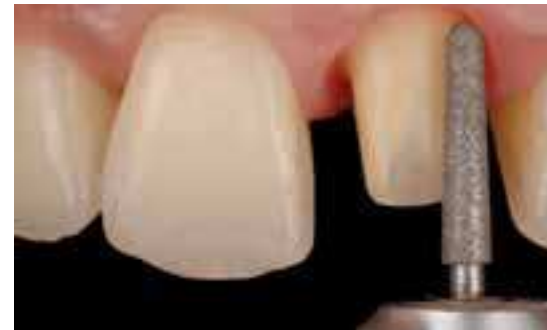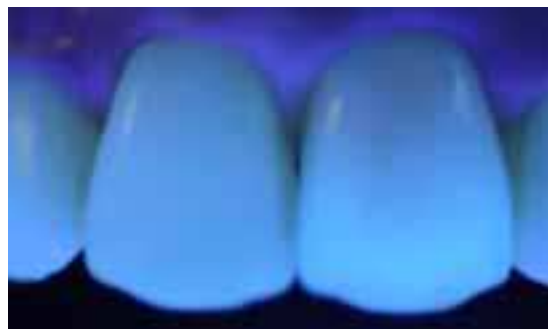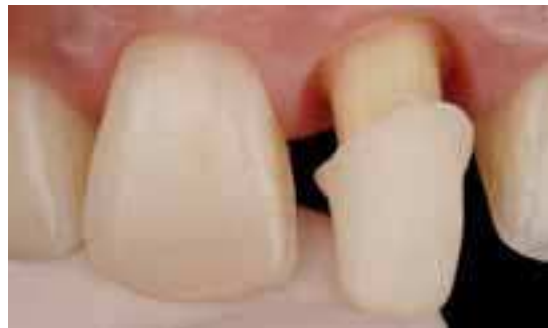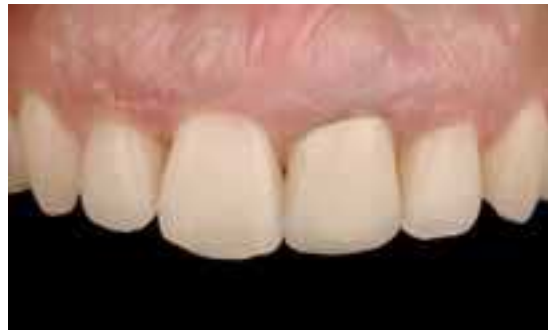Dr. Iñaki Gamborena, Spain

Frontal view of a PFM crown on the left central incisor. Notice the dark root discoloration in addition to the thin tissue thickness.

A Procera® Crown Alumina was chosen for optimal esthetic reasons and internal tooth bleaching was performed in order to create the maximum light transmission at the perio-prosthetic interface.

Buccal cutback (180°) of the coping was performed in order to favour fluorescence from the restoration into the root at the gingival area.

Note the similarity under ultraviolet light from the Procera® Crown Alumina to the natural tooth and the final esthetic result.



SINGLE TOOTH MISSING/  
IMPROVING EXISTING TEETH

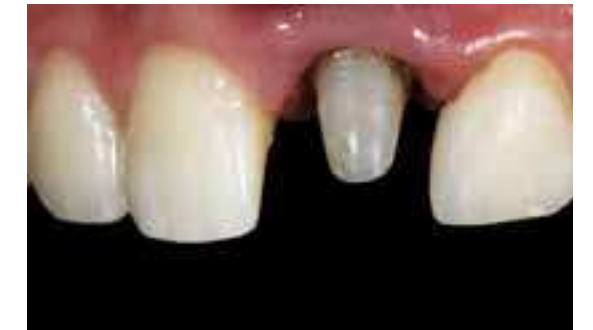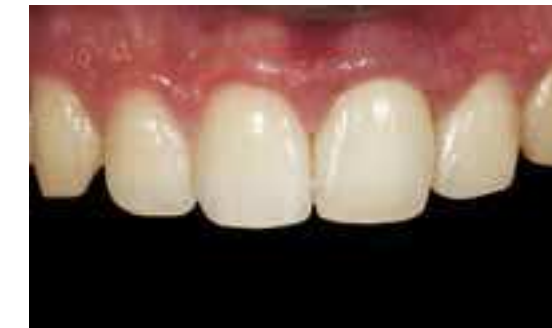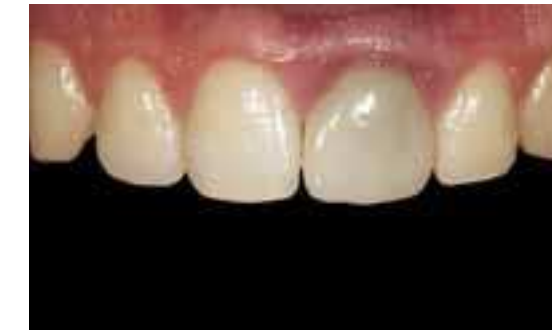## Procera® Crown Alumina

Dr. Dario Adolfi, Brazil & Dr. Carlos Moura Guedes, Portugal

The upper left central with full ceramic crown and lack of proportion crown x-width.

Retreatment of canal and esthetic post to help the natural transmission of light given by Procera® Crown Alumina. The upper left lateral was restored with composite resin in order to correct the interproximal contact point and interincisal angle.

Final restoration with NobelRondo™ Alumina porcelain with correct morphology, surface texture and superficial gloss.



SINGLE TOOTH MISSING/  
IMPROVING EXISTING TEETH

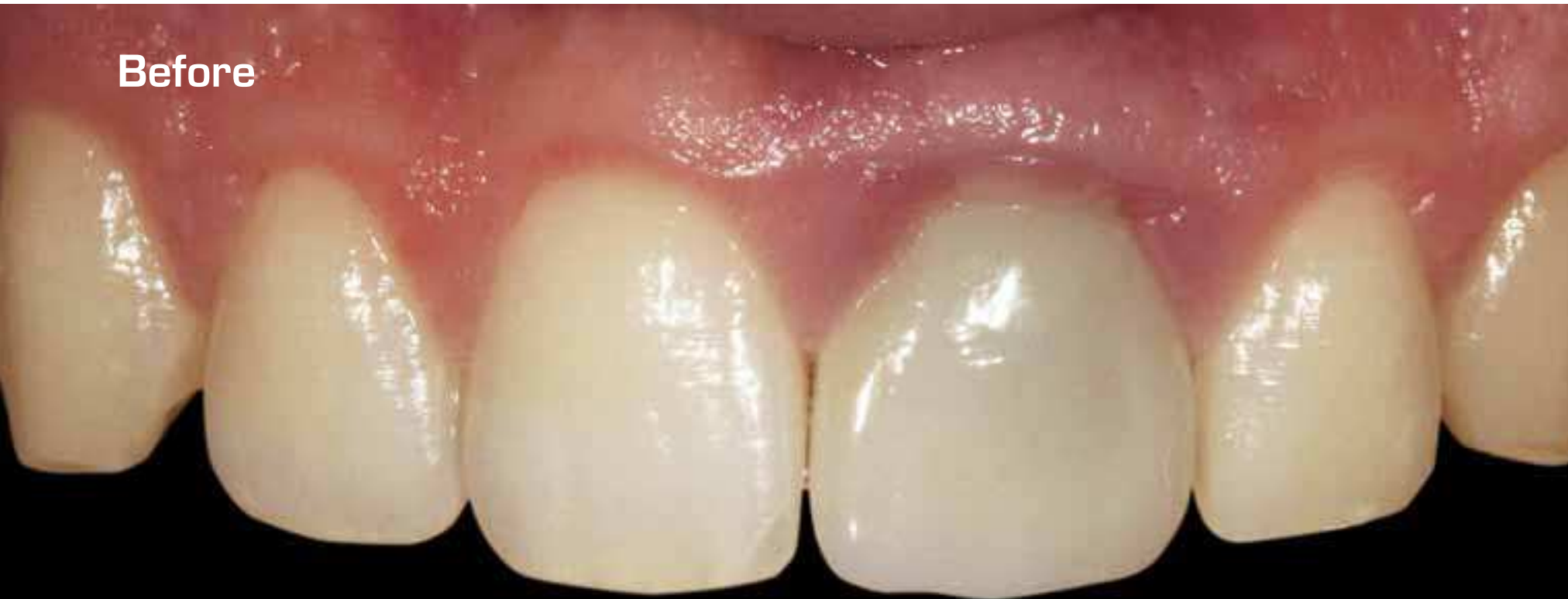## Procera® Crown Alumina

Dr. Dario Adolfi, Brazil & Dr. Carlos Moura Guedes, Portugal

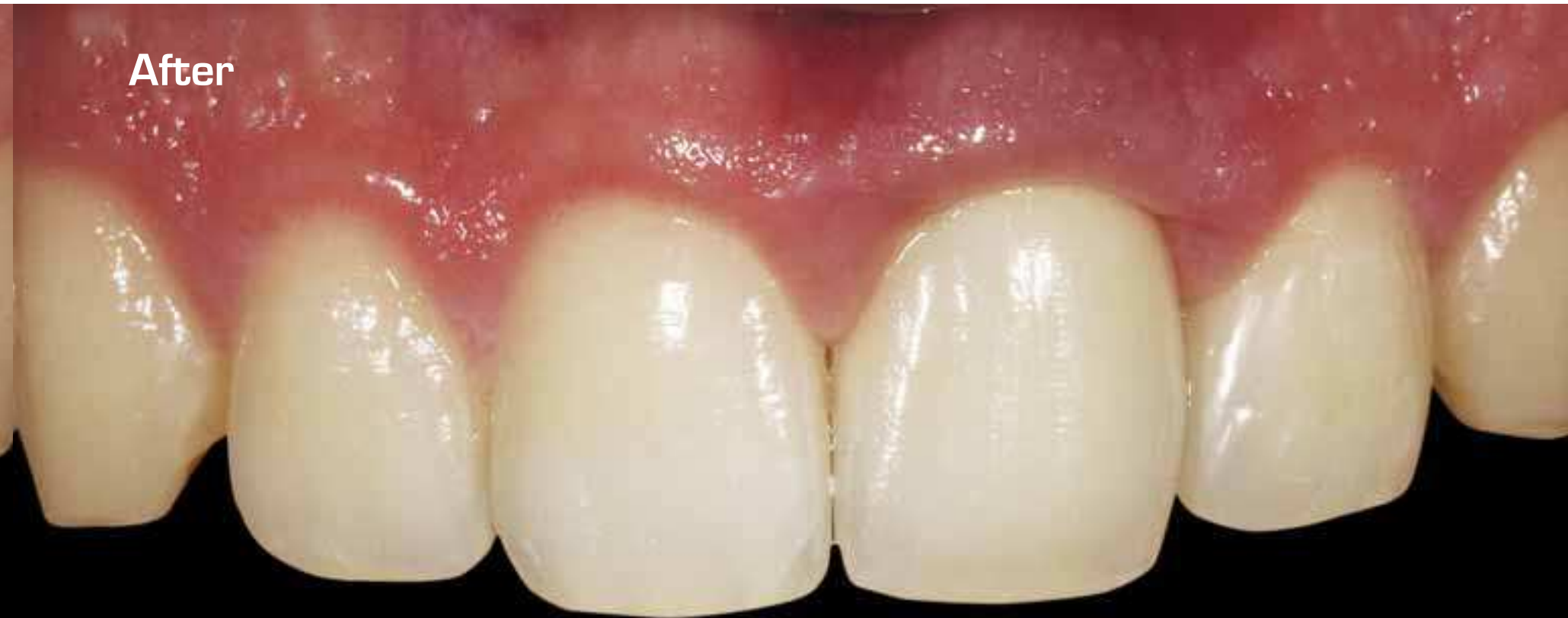SINGLE TOOTH MISSING/  
IMPROVING EXISTING TEETH

SINGLE TOOTH MISSING/  
IMPROVING EXISTING TEETH

**Before**



**After**



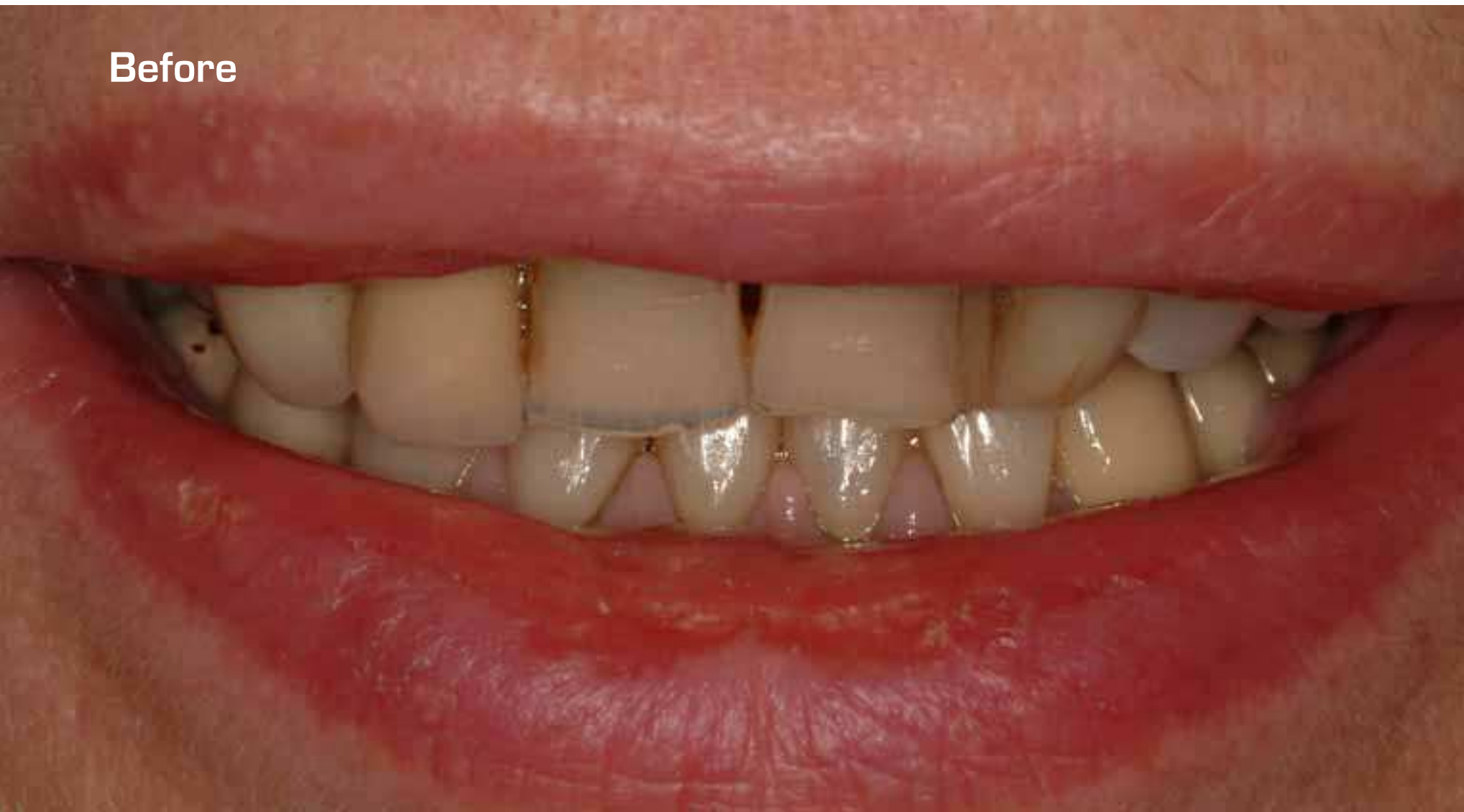

Procera® Crown Alumina

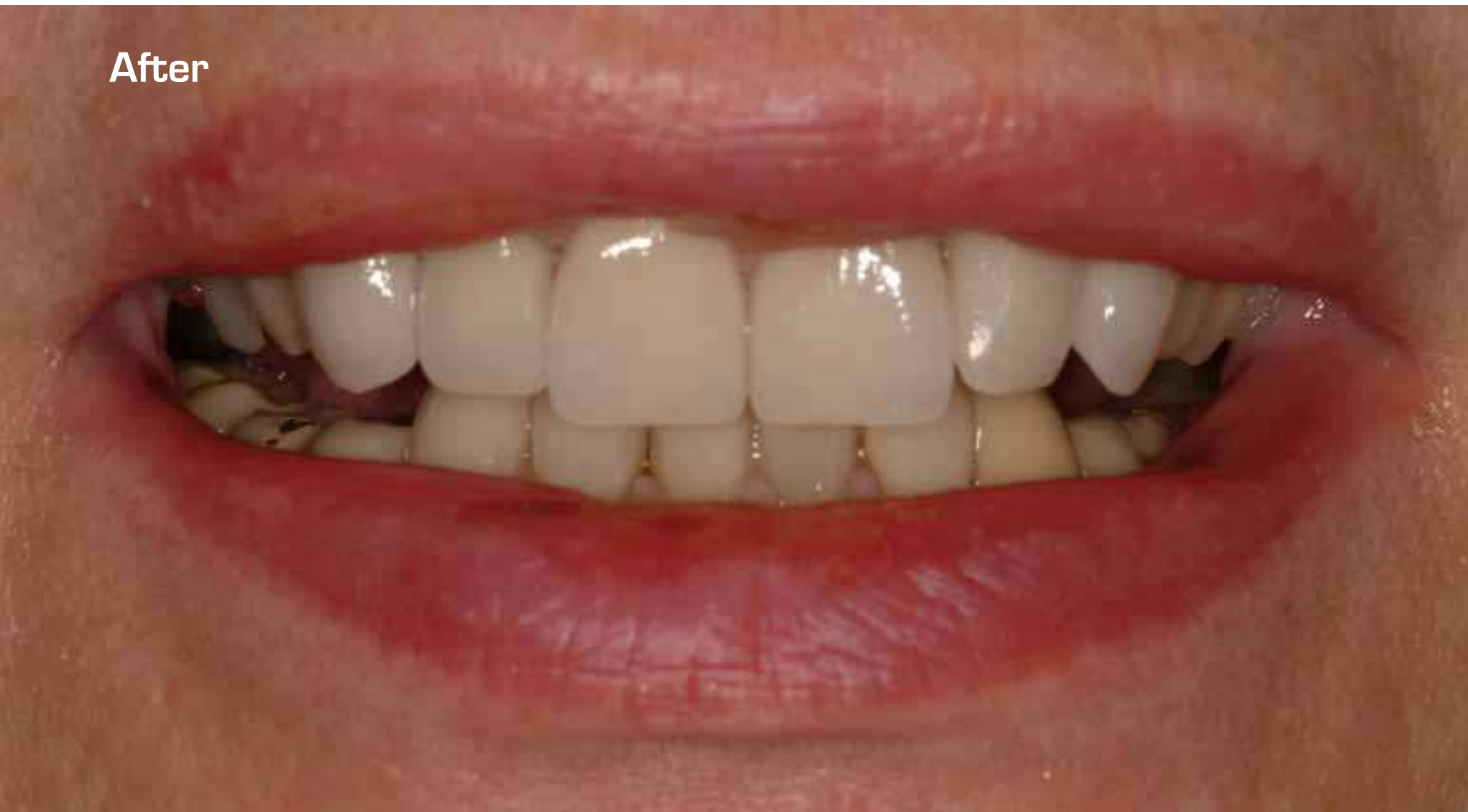Dr. Jonathan L Ferencz, USA

SINGLE TOOTH MISSING/  
IMPROVING EXISTING TEETH

Before



After



SINGLE TOOTH MISSING/  
IMPROVING EXISTING TEETH



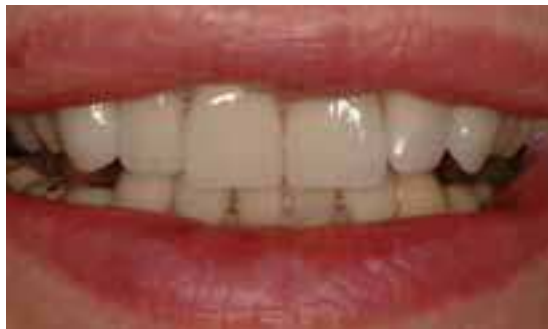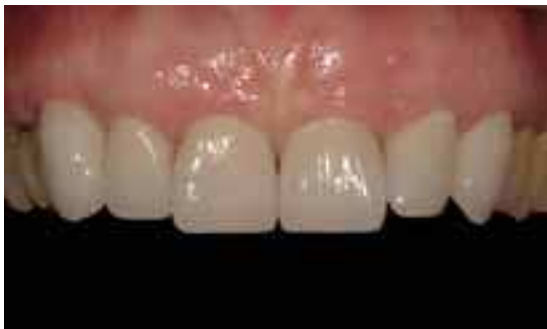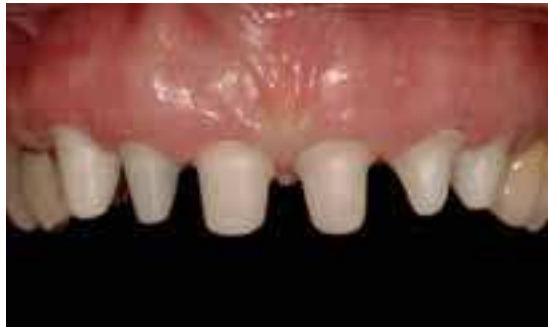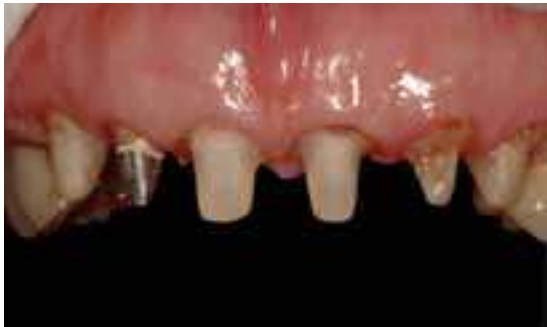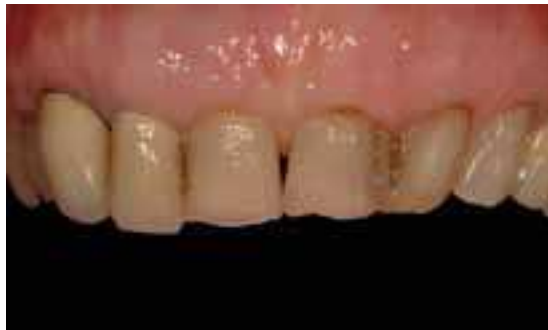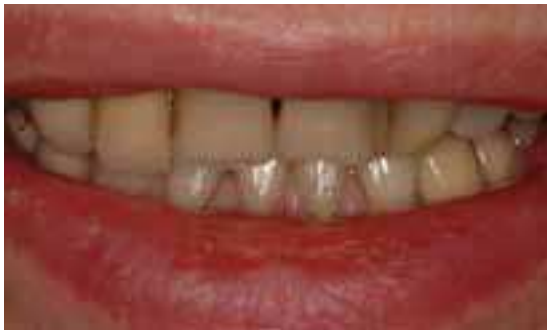# Procera® Crown Alumina

Dr. Jonathan L Ferencz, USA

The patient was very unhappy with the appearance of her smile. In particular, she did not like the discoloration of her old fillings, the dark gingival margins of the metal-ceramic crowns on the right canine and lateral incisor and the irregular incisal edges of the six anteriors.

The preparations are shown on the left photo and the Procera® Alumina cores tried in on the right photo. Notice the darkness of some of the preparations, especially the metallic post and core on the right lateral incisor. The teeth have been prepared with rounded chamfers.

The completed construction of six Procera® Crown Alumina are shown. The veneering ceramic was Nobel-Rondo™ Alumina. The laboratory phase of the treatment was done by Pasquale Fanetti.



SINGLE TOOTH MISSING/  
IMPROVING EXISTING TEETH

# Procera® Crown Alumina Procera® Laminate

Dr. Mauro Fradeani & Mr. Giancarlo Barducci, Italy

The patient wanted to have the old failed crowns replaced and to eliminate the slight rotation of the left lateral incisor.

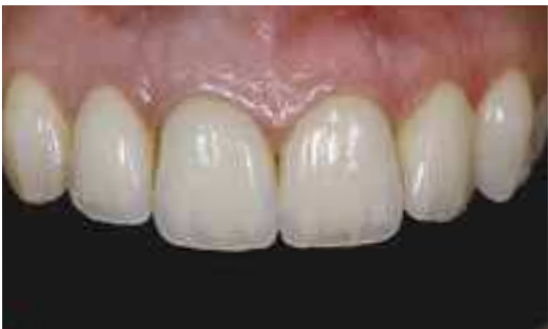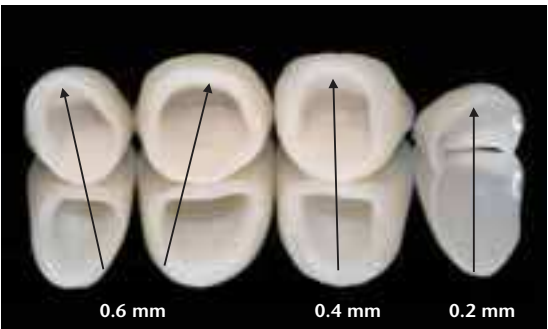
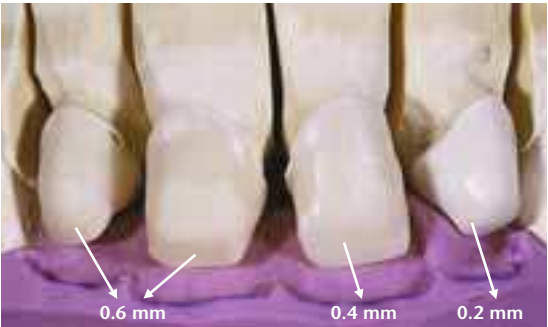
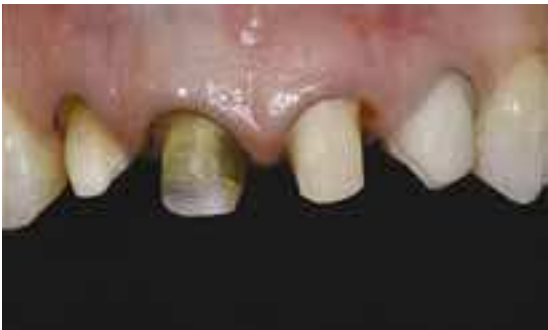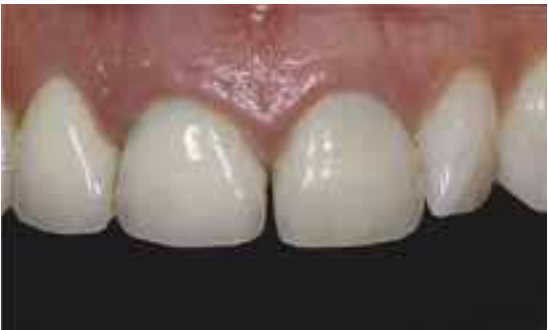Preparation completed for three Procera® Crowns and Procera® Laminate. Note the severe discoloration on right lateral and central incisors.

In order to optimize the esthetic outcome, different coping thickness were selected to compensate for the different color of underneath abutments.

The layering procedure was performed following the silicon index derived from an esthetically and functionally well-integrated provisional.

Note the difference in thickness of the completed layered restorations.

Beautiful esthetic final result. Note the translucency of the Procera® Crowns and the well-adapted soft tissue margins.



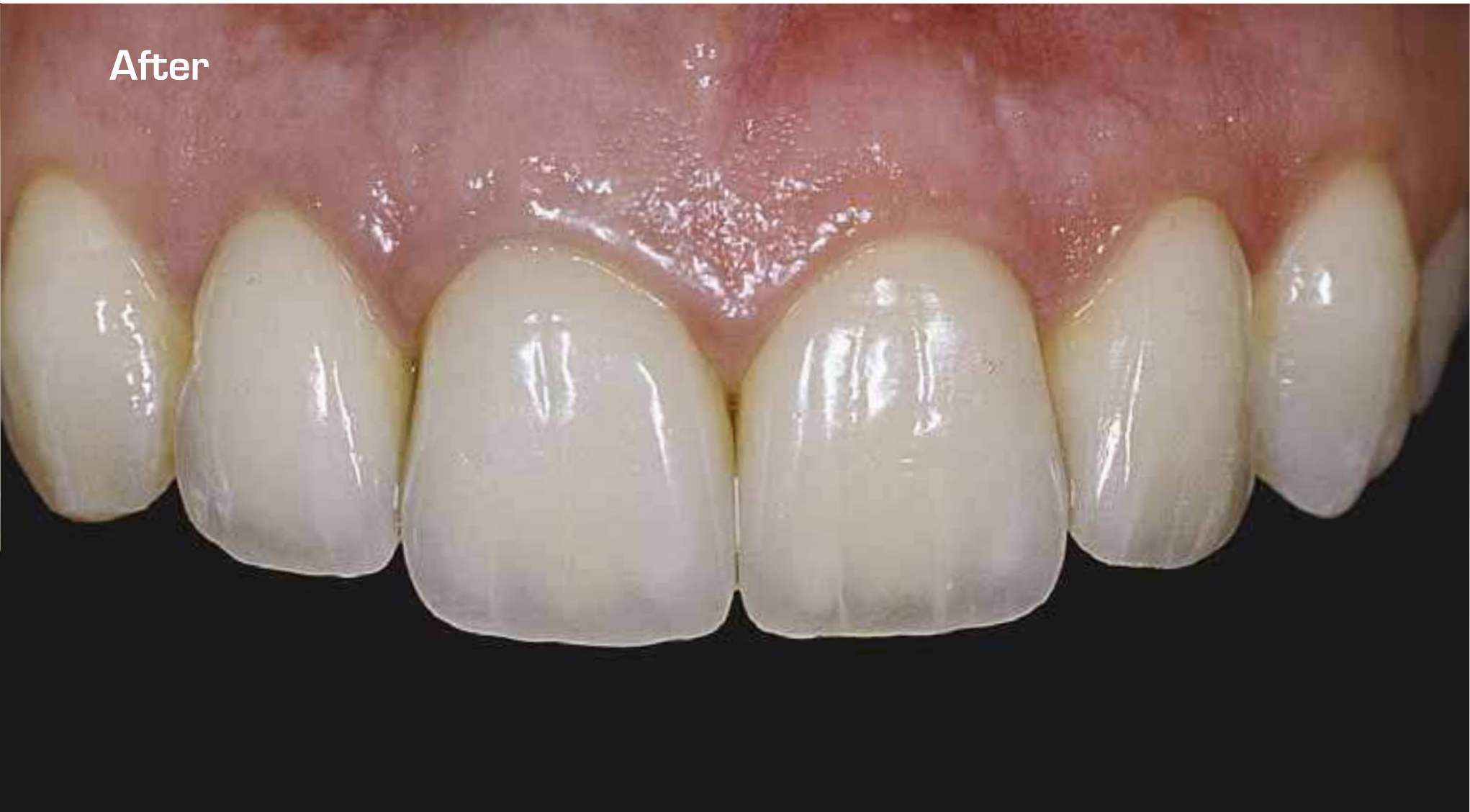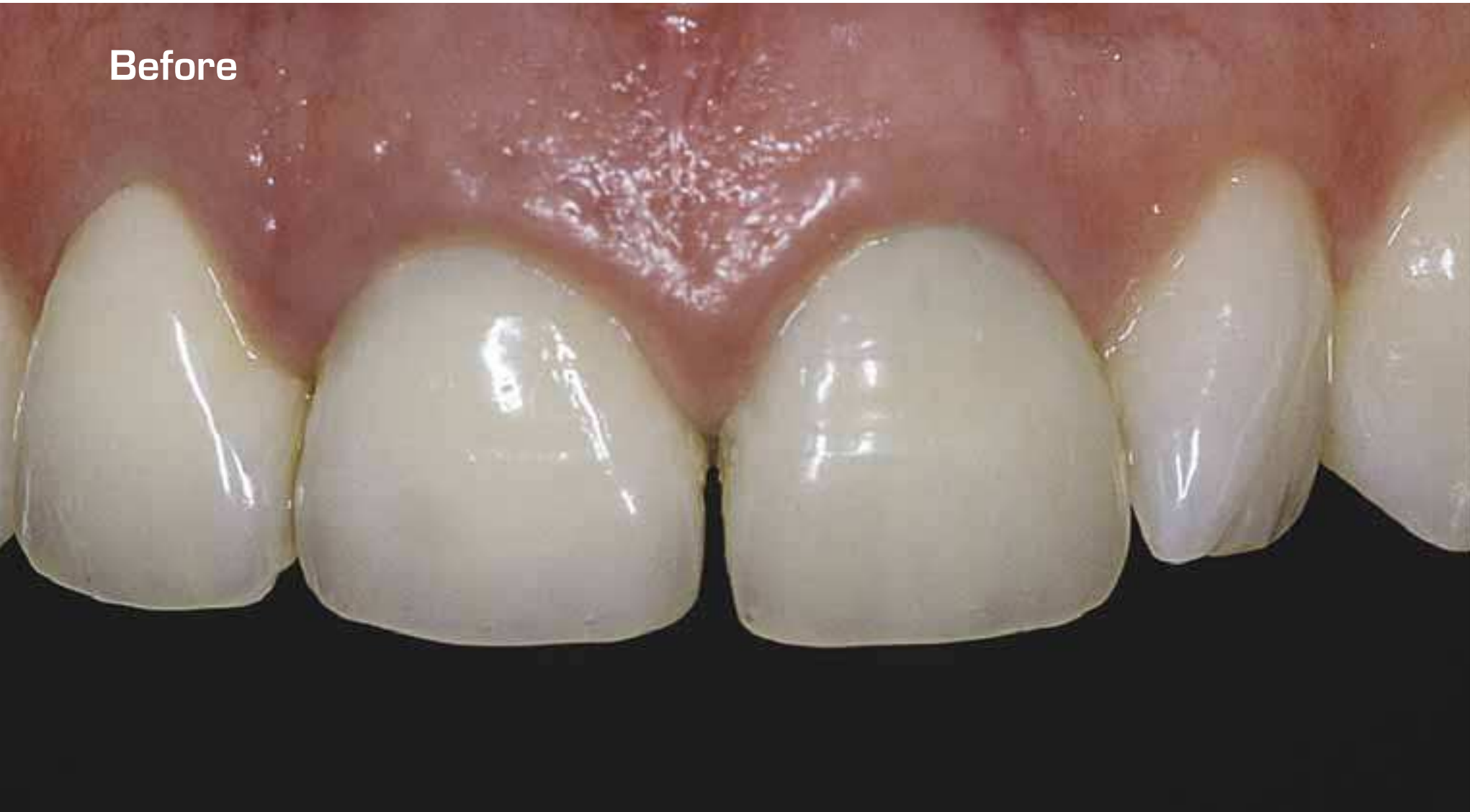SINGLE TOOTH MISSING/  
IMPROVING EXISTING TEETH

Procera® Crown Alumina  
Procera® Laminate

Dr. Mauro Fradeani & Mr. Giancarlo Barducci, Italy

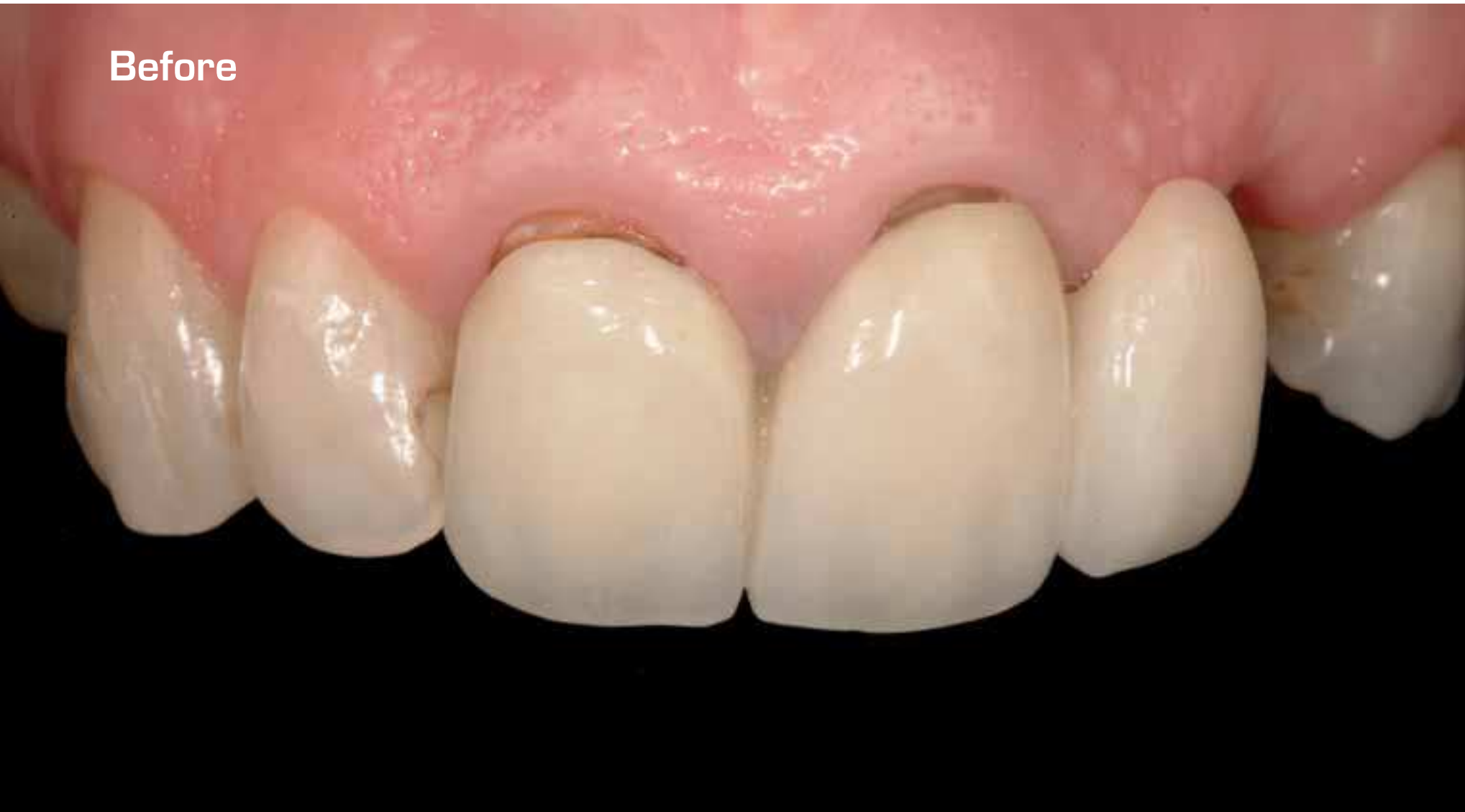SINGLE TOOTH MISSING/  
IMPROVING EXISTING TEETH

SINGLE TOOTH MISSING/  
IMPROVING EXISTING TEETH

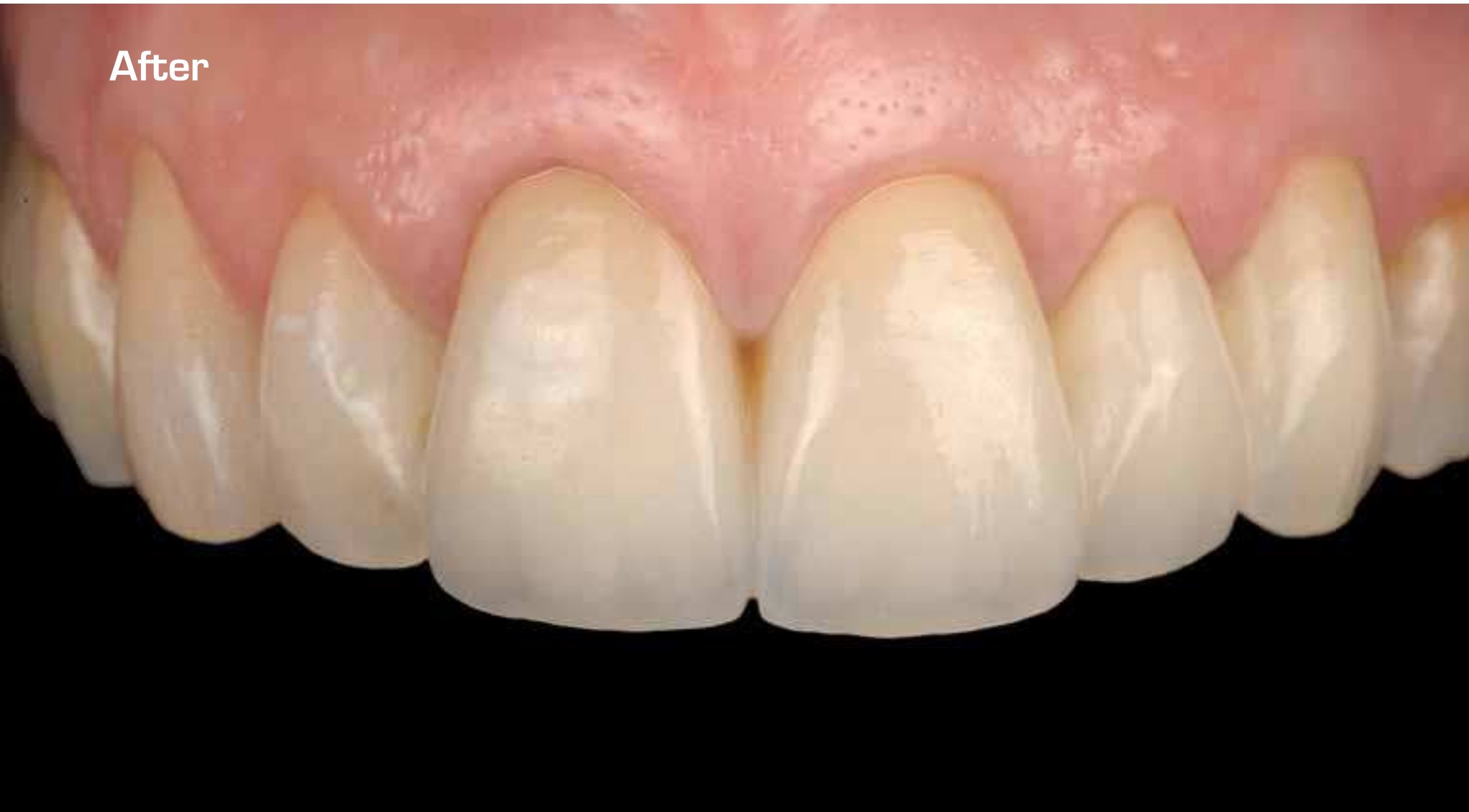



Before



After



## Procera® Bridge Zirconia

Dr. Iñaki Gamborena, Spain

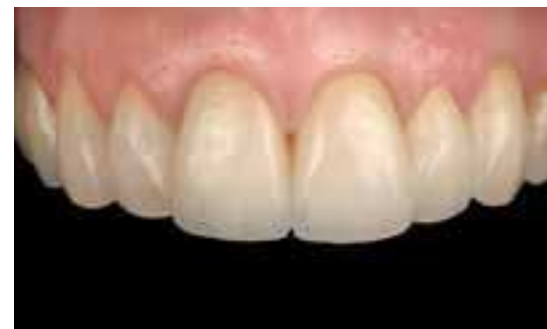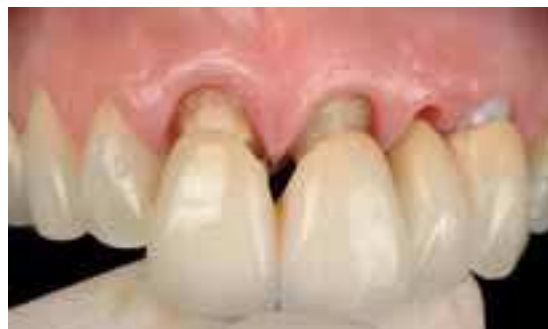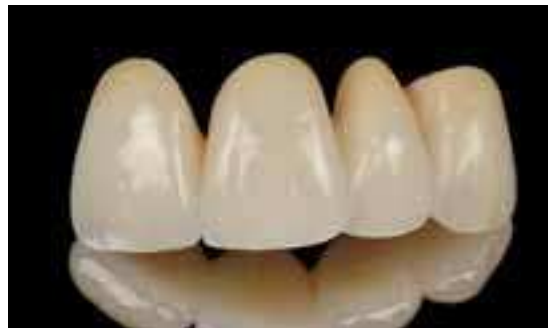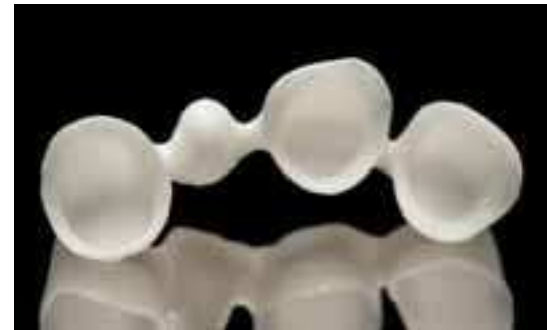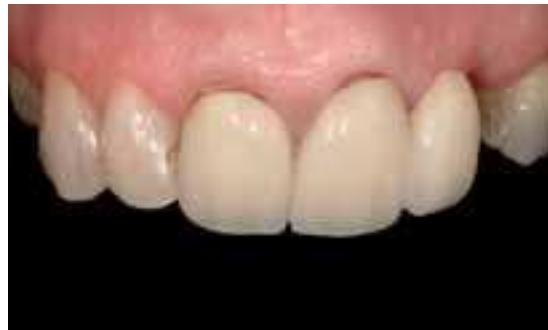A female patient presented with an anterior FPD extending from the maxillary right central incisor to the cantilevered left lateral incisor.

The left canine had been previously extracted resulting in a significant loss of hard and soft tissue in that area. A Replace® Select implant was placed on the left canine as well as two ridge augmentation procedures with connective-tissue grafts.

A crown-lengthening procedure was also performed in order to level gingival margins and create proportioned anterior restorations. Following the re-evaluation the implant was connected rigidly to both central incisors using a 4-unit Procera® Bridge Zirconia.

The excellent physical and esthetic properties of the zirconia were taken into consideration at the time of selecting this material.

Notice the optimal esthetic integration of the Procera® Bridge Zirconia in the anterior esthetic zone.



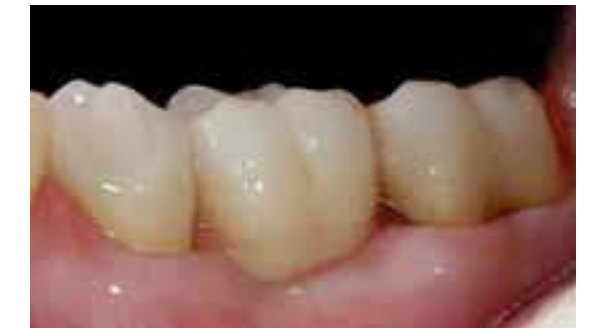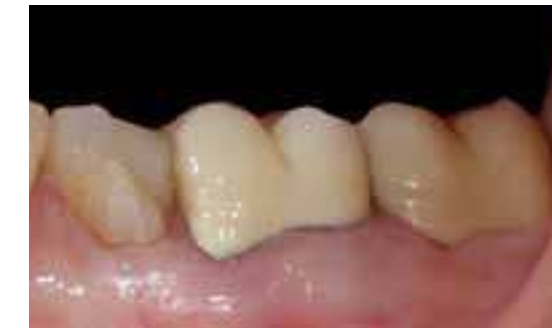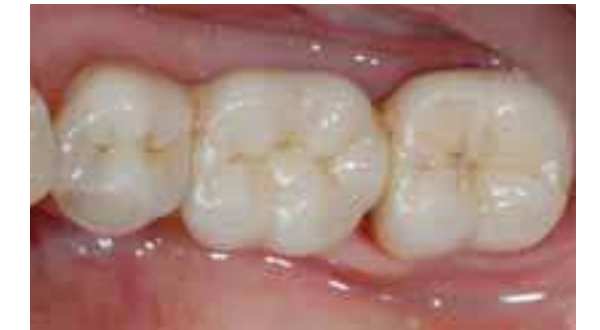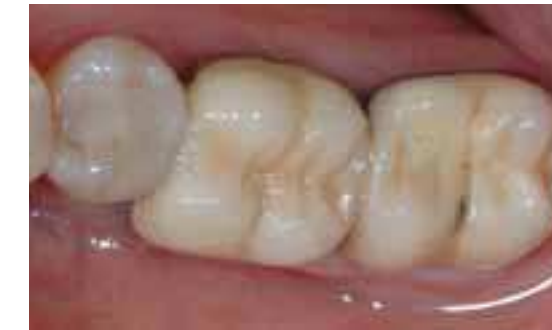## SINGLE TOOTH MISSING/ IMPROVING EXISTING TEETH

## Procera® Bridge Zirconia

Dr. Mauro Riva, Mr. Davide Riva & Mr. Levino Nicotra, Italy

The patient had decay in tooth 36 due to an old failed crown.

After the extraction of 36, the endodontic re-treatment and die core build-up of 35 with an old composite filling, crown removal and endodontic re-treatment of 37, the case was finalized with a Procera® Bridge Zirconia and NobelRondo™ Ceramics.



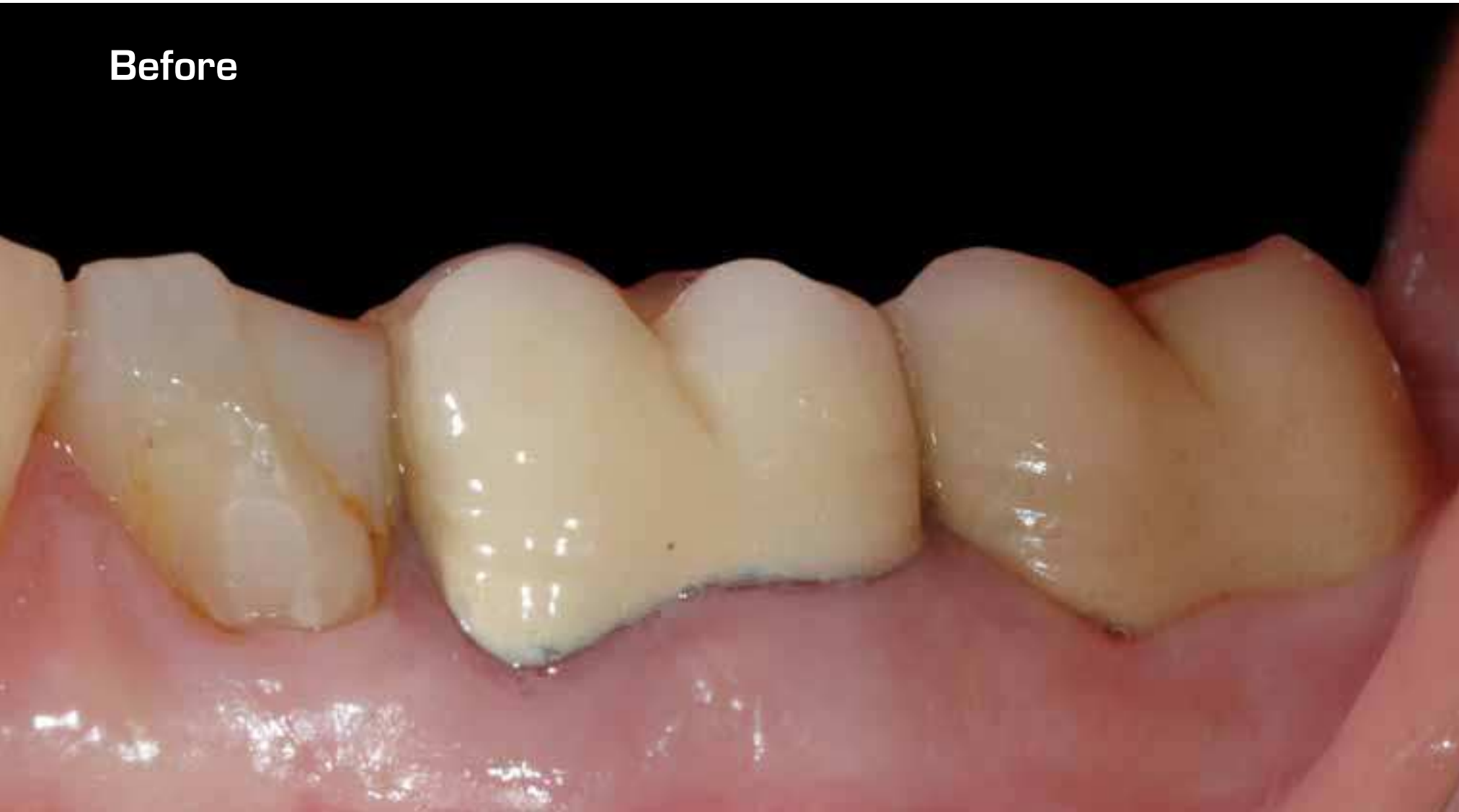

## Procera® Bridge Zirconia

Dr. Mauro Riva, Mr. Davide Riva & Mr. Levino Nicotra, Italy

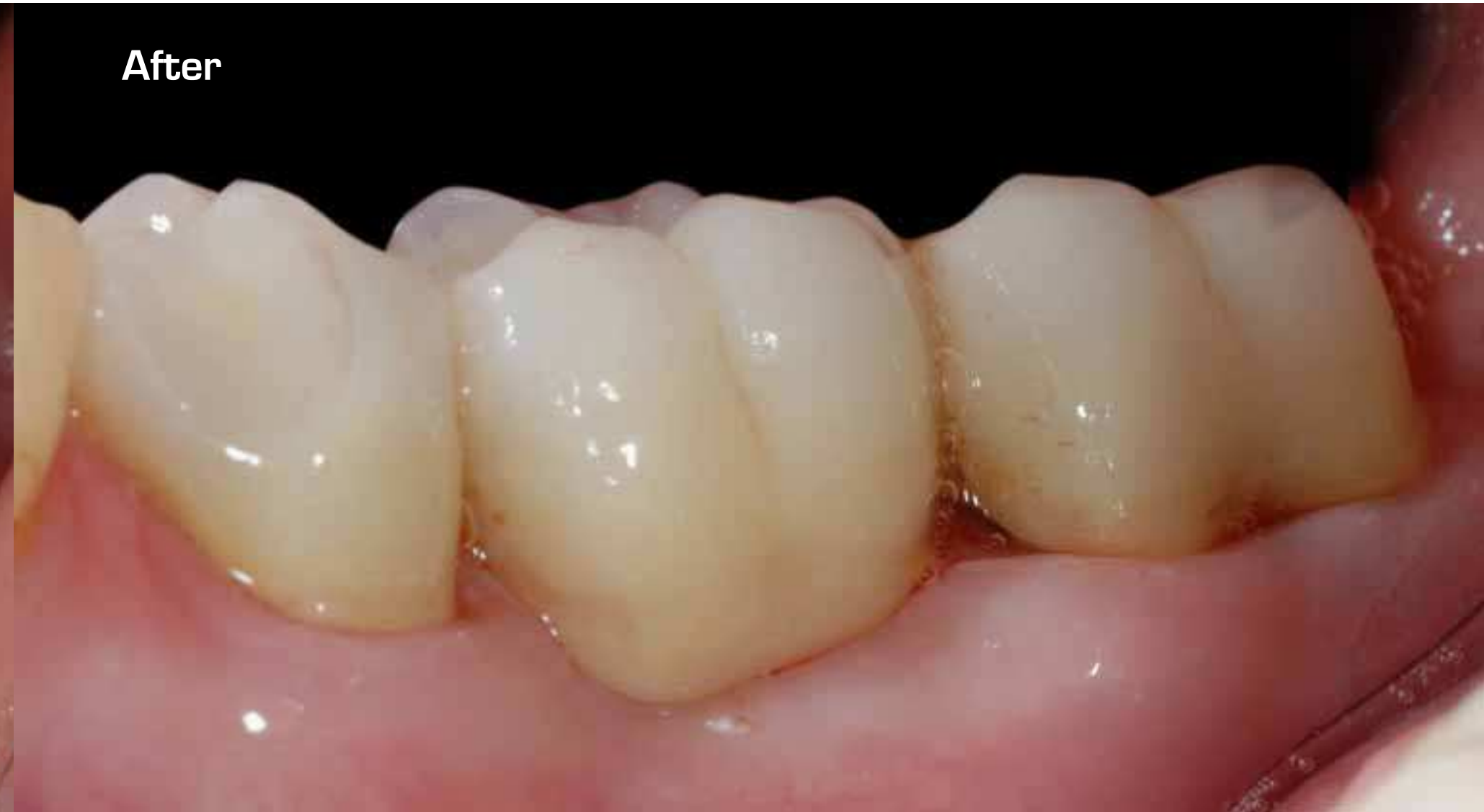SINGLE TOOTH MISSING/  
IMPROVING EXISTING TEETH

**Before**



30

**After**



SINGLE TOOTH MISSING/  
IMPROVING EXISTING TEETH

31

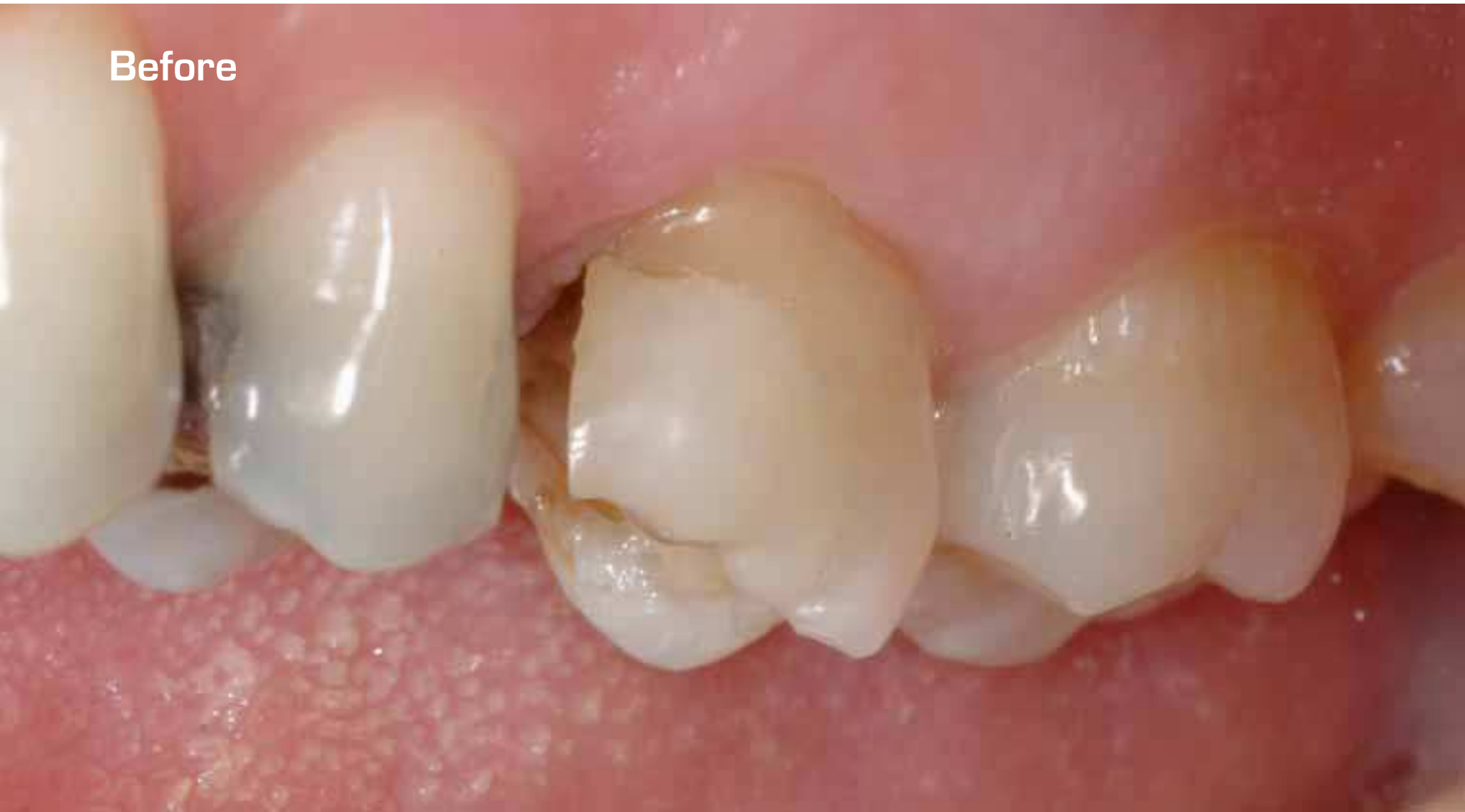Procera® Crown Alumina

Dr. Mauro Riva & Mr. Davide Riva, Italy

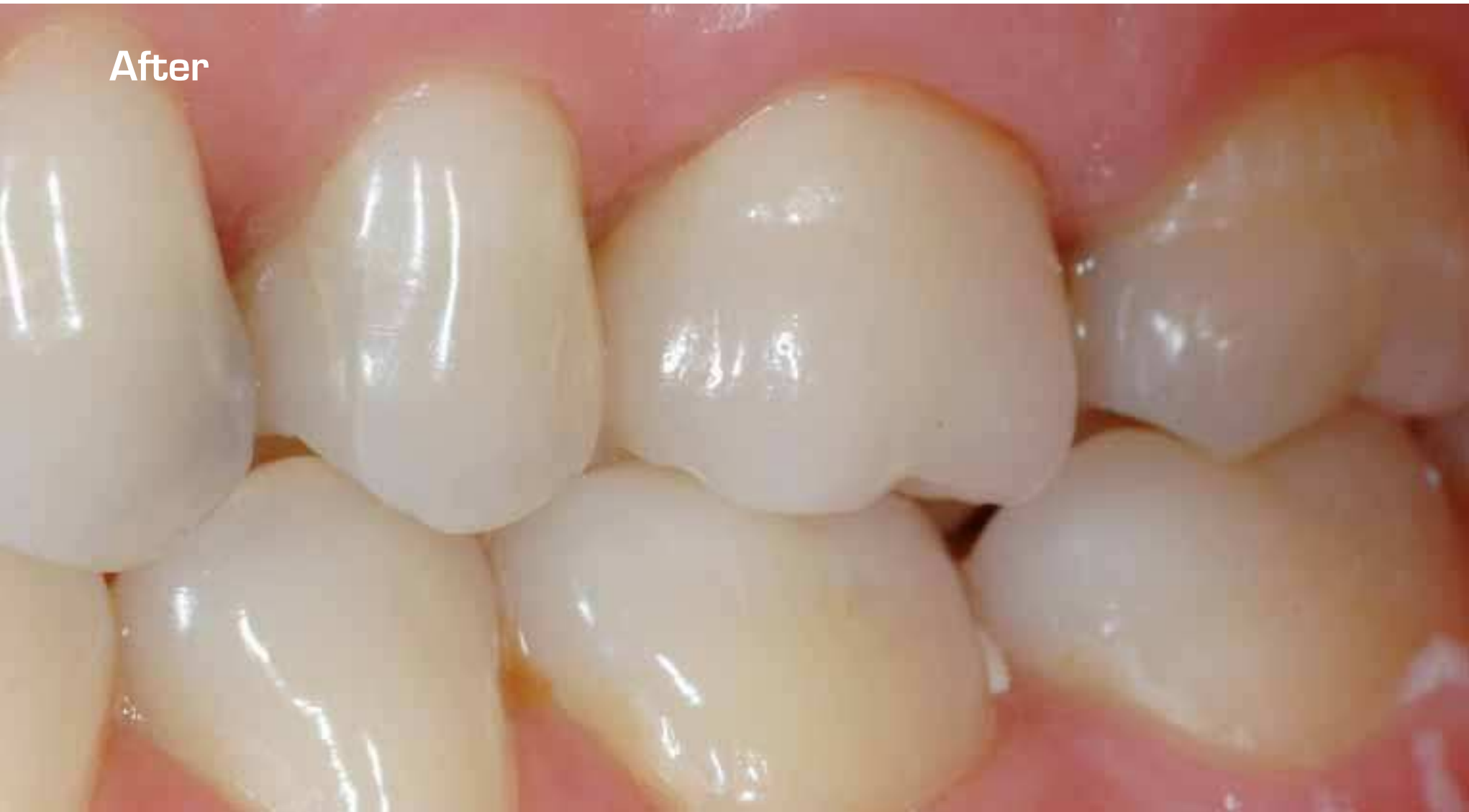SINGLE TOOTH MISSING/  
IMPROVING EXISTING TEETH

SINGLE TOOTH MISSING/  
IMPROVING EXISTING TEETH

Before



After

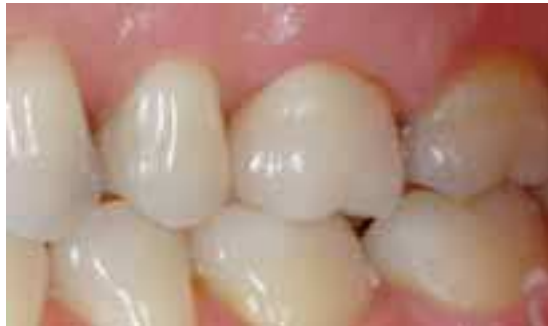
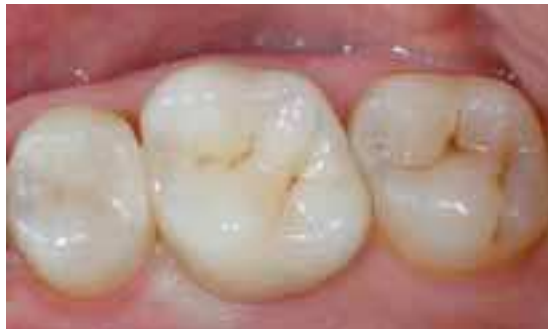
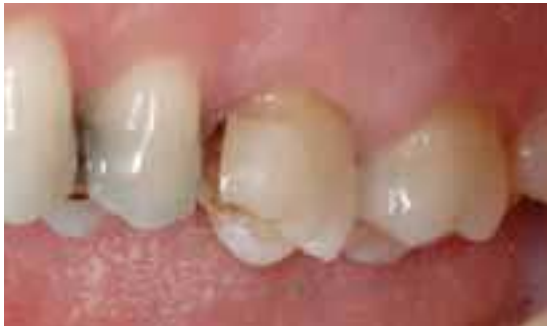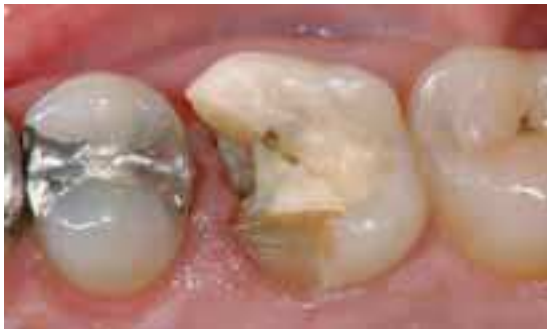Procera® Crown Alumina

Dr. Mauro Riva & Mr. Davide Riva, Italy

Fracture of the old mesias-occlusal amalgam filling of tooth 26.

After the root canal re-treatment and consecutive die core build-up, the case was finalized with a Procera® Crown Alumina and NobelRondo™ Ceramics.



SINGLE TOOTH MISSING/  
IMPROVING EXISTING TEETH

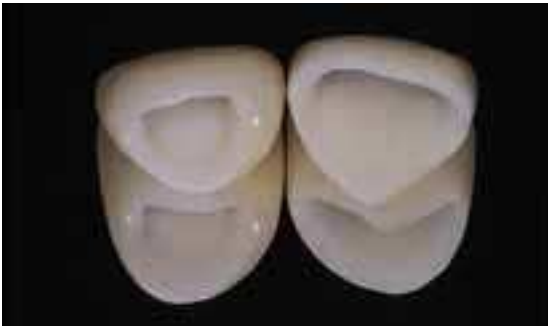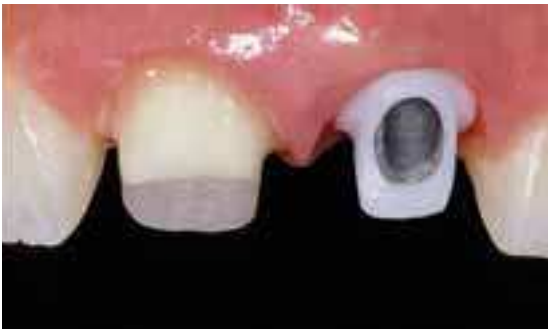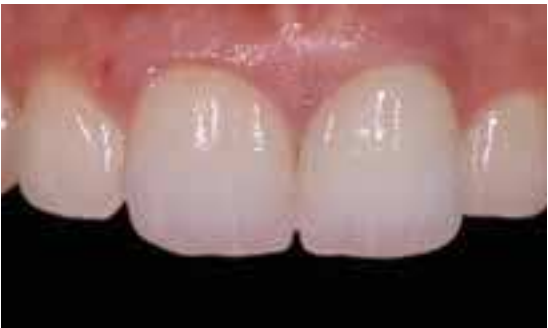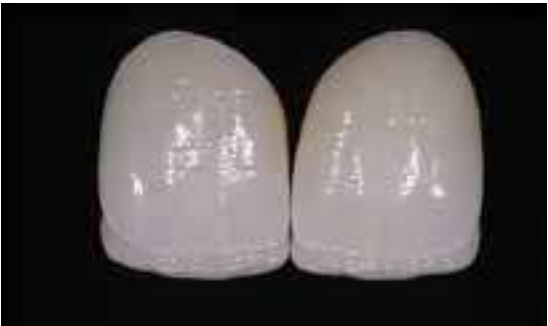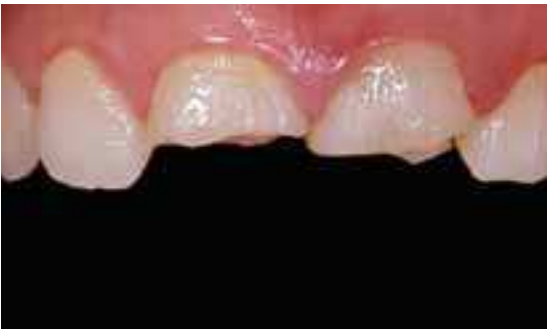Procera® Crown Alumina  
Procera® Abutment Zirconia

Dr. Mauro Fradeani & Mr. Giancarlo Barducci, Italy

The 20-year-old patient presented with her two central incisors fractured in a car crash.

Due to the vertical root breakage on the left central incisor, the tooth was extracted and an implant with a Procera® Abutment Zirconia was inserted.

Reconstruction was performed on the right central incisor. The case was finalized with two Procera® Crown Alumina.



SINGLE TOOTH MISSING/  
IMPROVING EXISTING TEETH

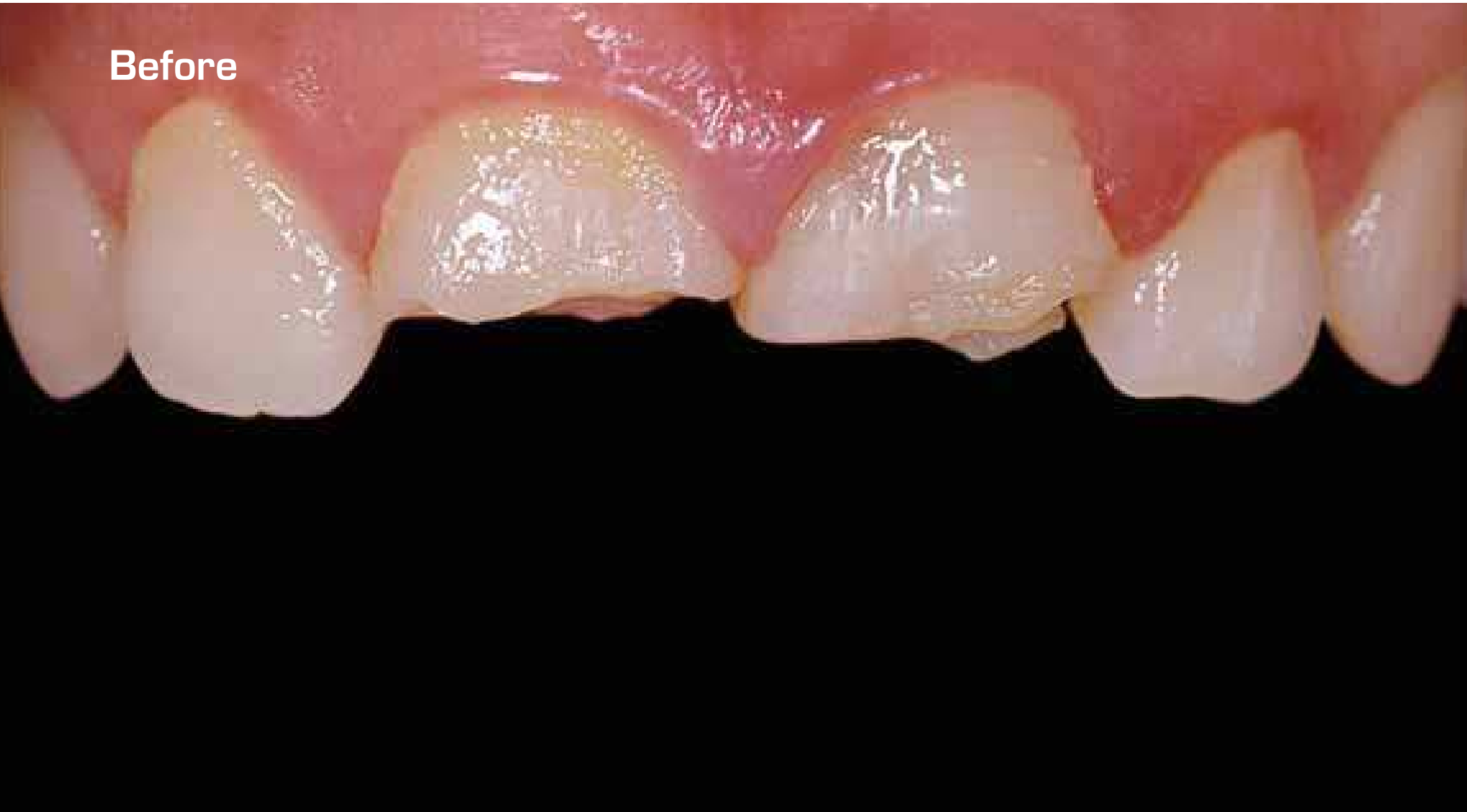Procera® Crown Alumina  
Procera® Abutment Zirconia

Dr. Mauro Fradeani & Mr. Giancarlo Barducci, Italy

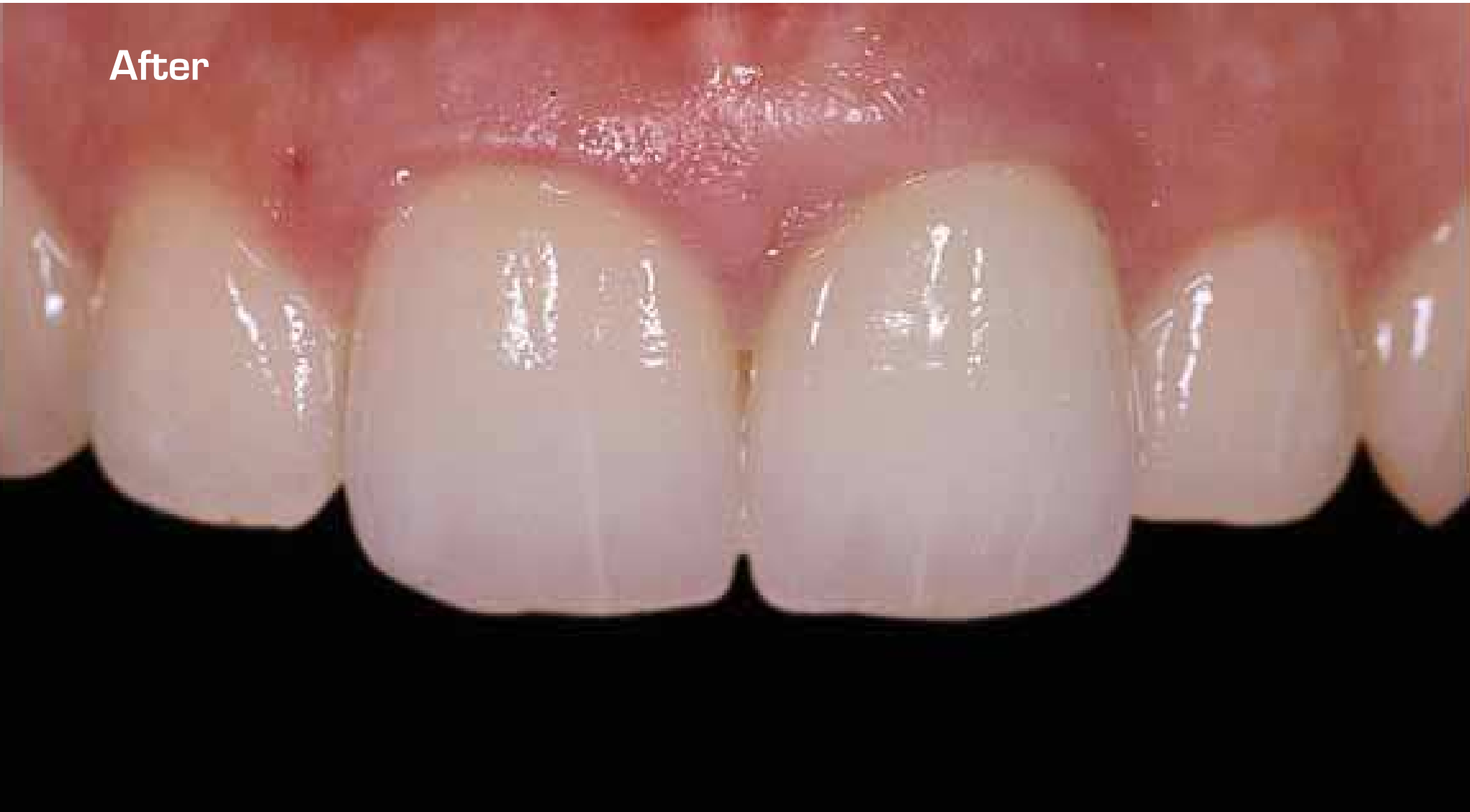SINGLE TOOTH MISSING/  
IMPROVING EXISTING TEETH

SINGLE TOOTH MISSING/  
IMPROVING EXISTING TEETH

Before

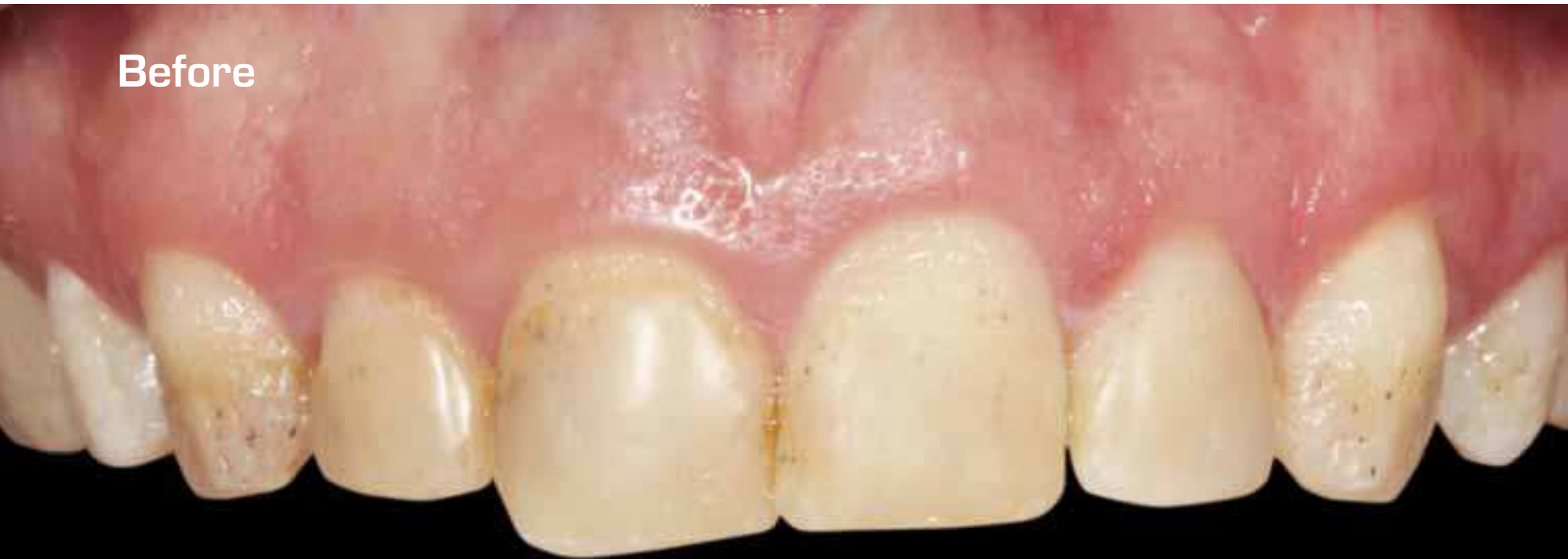

After

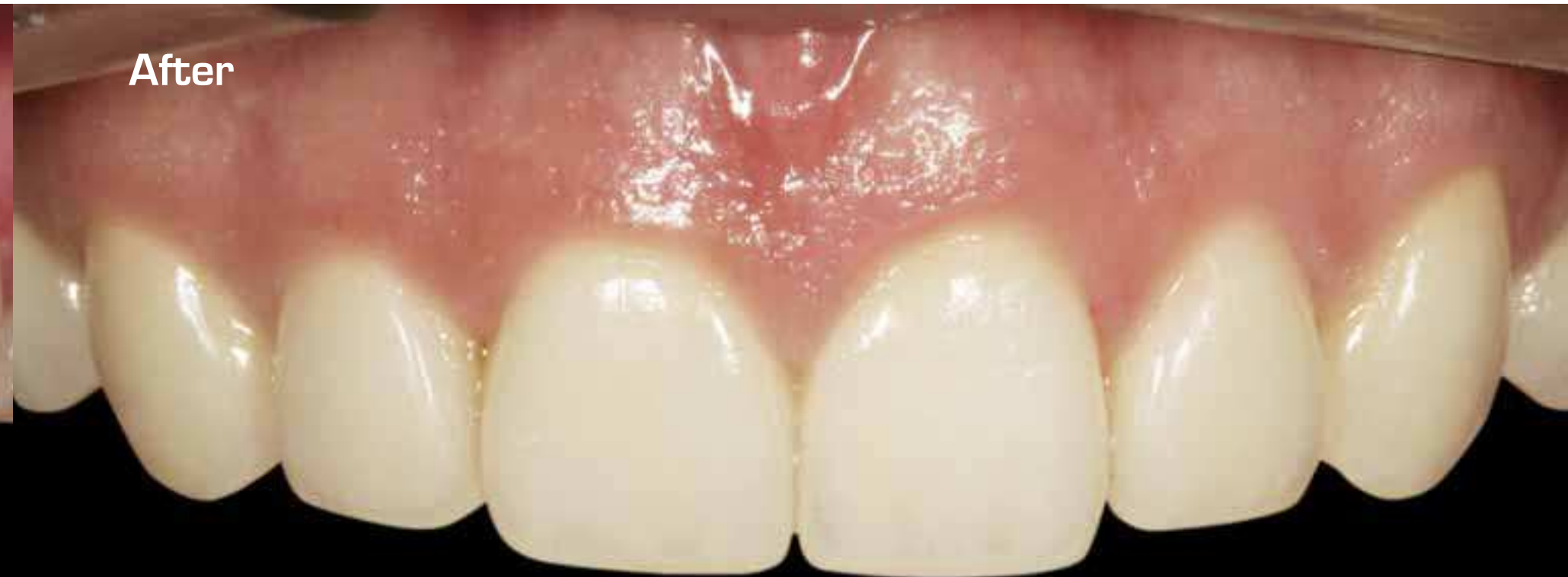



Before



After



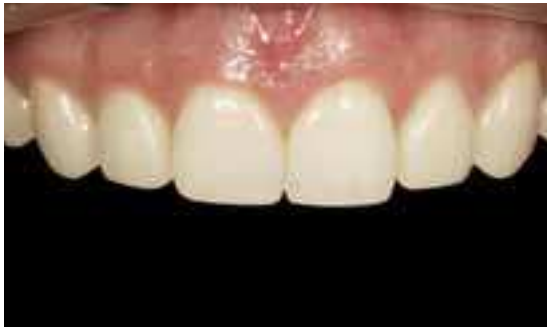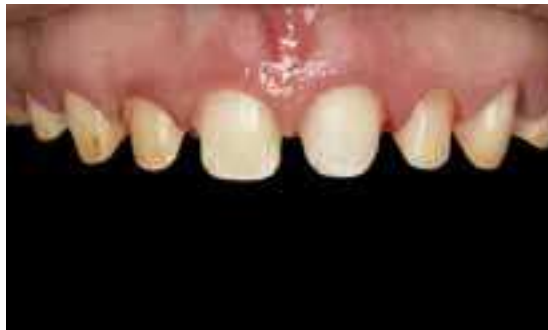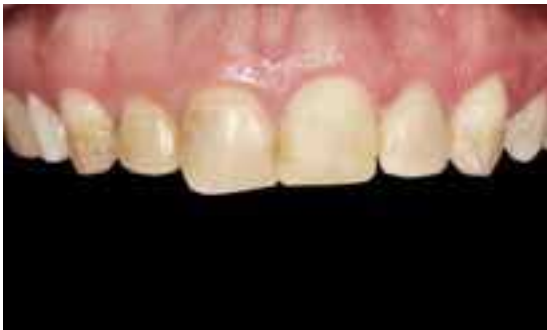# Procera® Crown

Dr. Dario Adolfi, Brazil & Dr. Carlos Moura Guedes, Portugal

All the teeth had amelogenesis imperfecta, which is a genetic defect that results in no enamel or poor enamel formation.

Adequate preparation for Procera® Crown Alumina to receive 0.4 mm copings, pre-molar to pre-molar and 0.6 mm for molars.

High-quality esthetic outcome with NobelRondo™ Alumina Ceramics and cementation with glass ionomer material.



SINGLE TOOTH MISSING/  
IMPROVING EXISTING TEETH

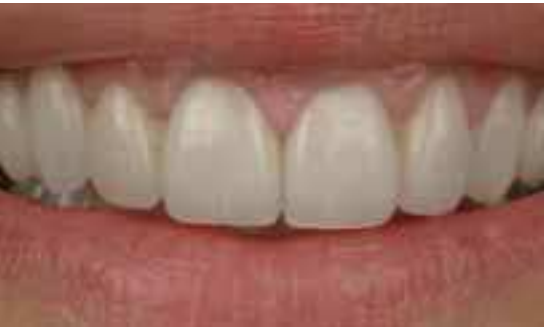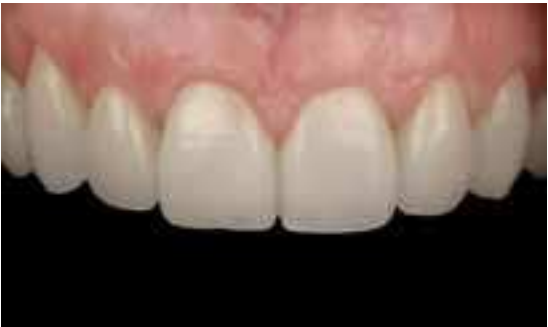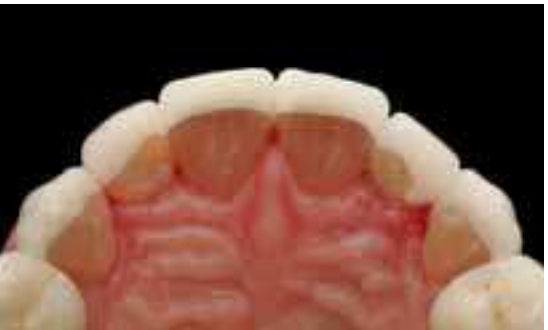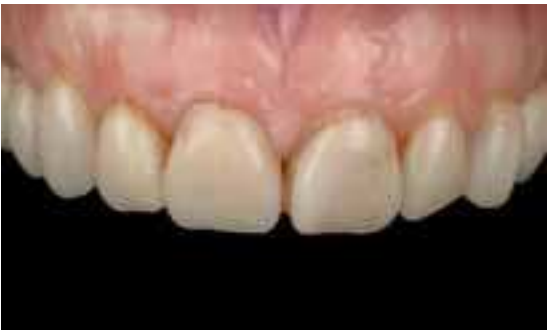# Procera® Laminate

Dr. Iñaki Gamborena, Spain

Female patient presented with broken and poorly adjusted feldespatic porcelain laminates on really dark tetracycline teeth.

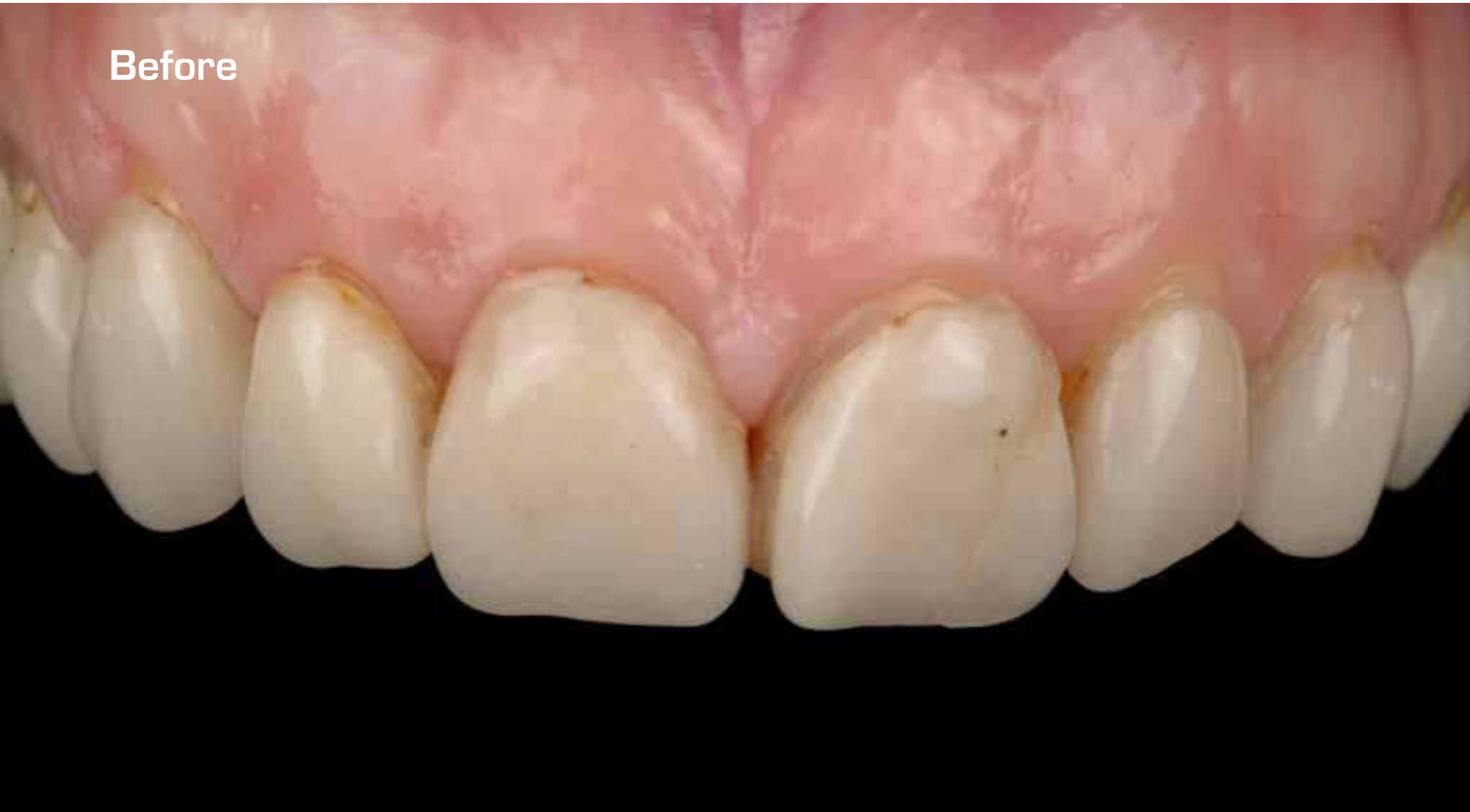Procera® Laminate were selected in this particular case to mask as much as possible of the dark tetracycline staining. The 0.25 mm alumina laminate creates in this way a uniform color block-out.

You can see the final esthetic result accomplished with the Procera® Laminate and its integration within the tissues.

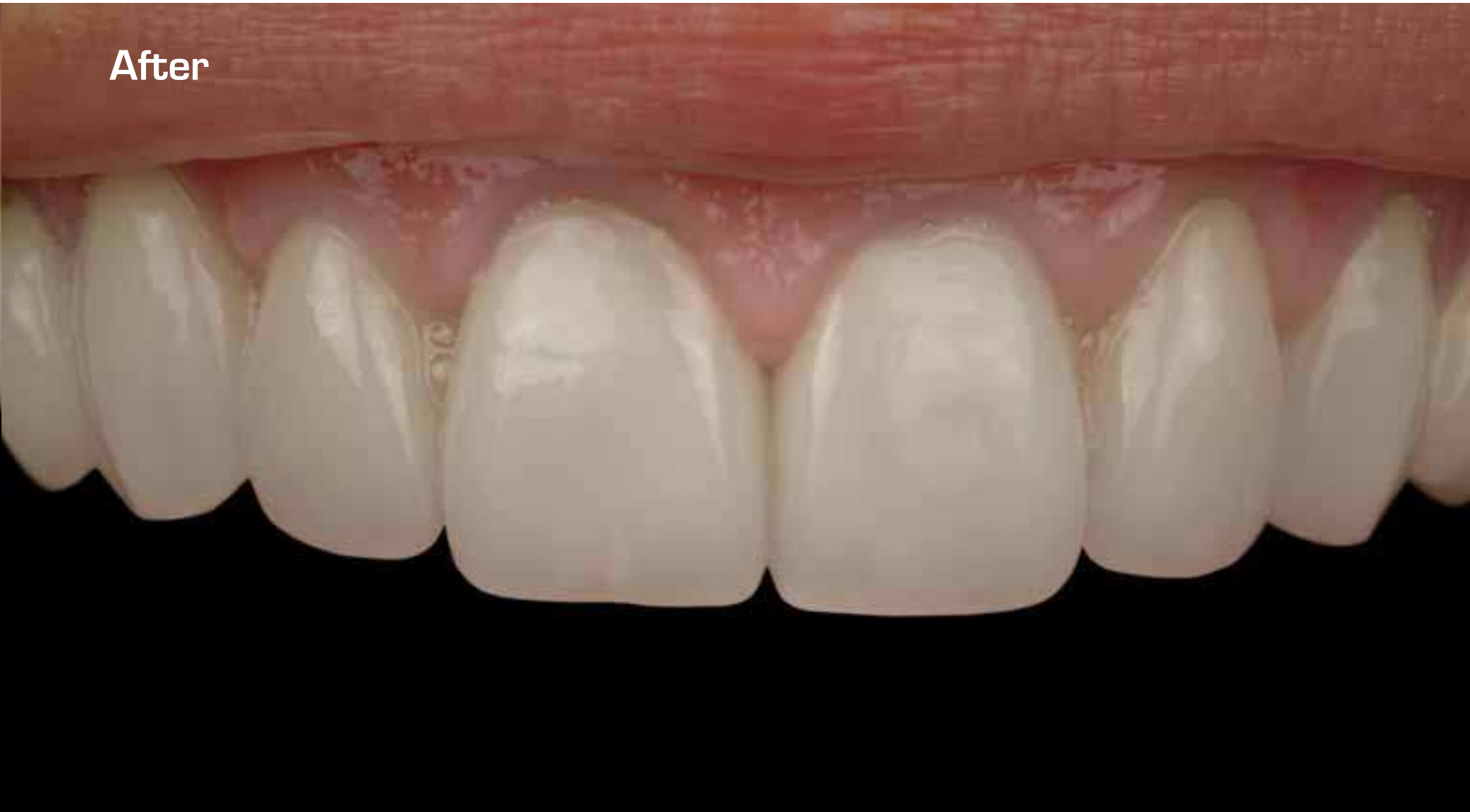

SINGLE TOOTH MISSING/  
IMPROVING EXISTING TEETH

Before

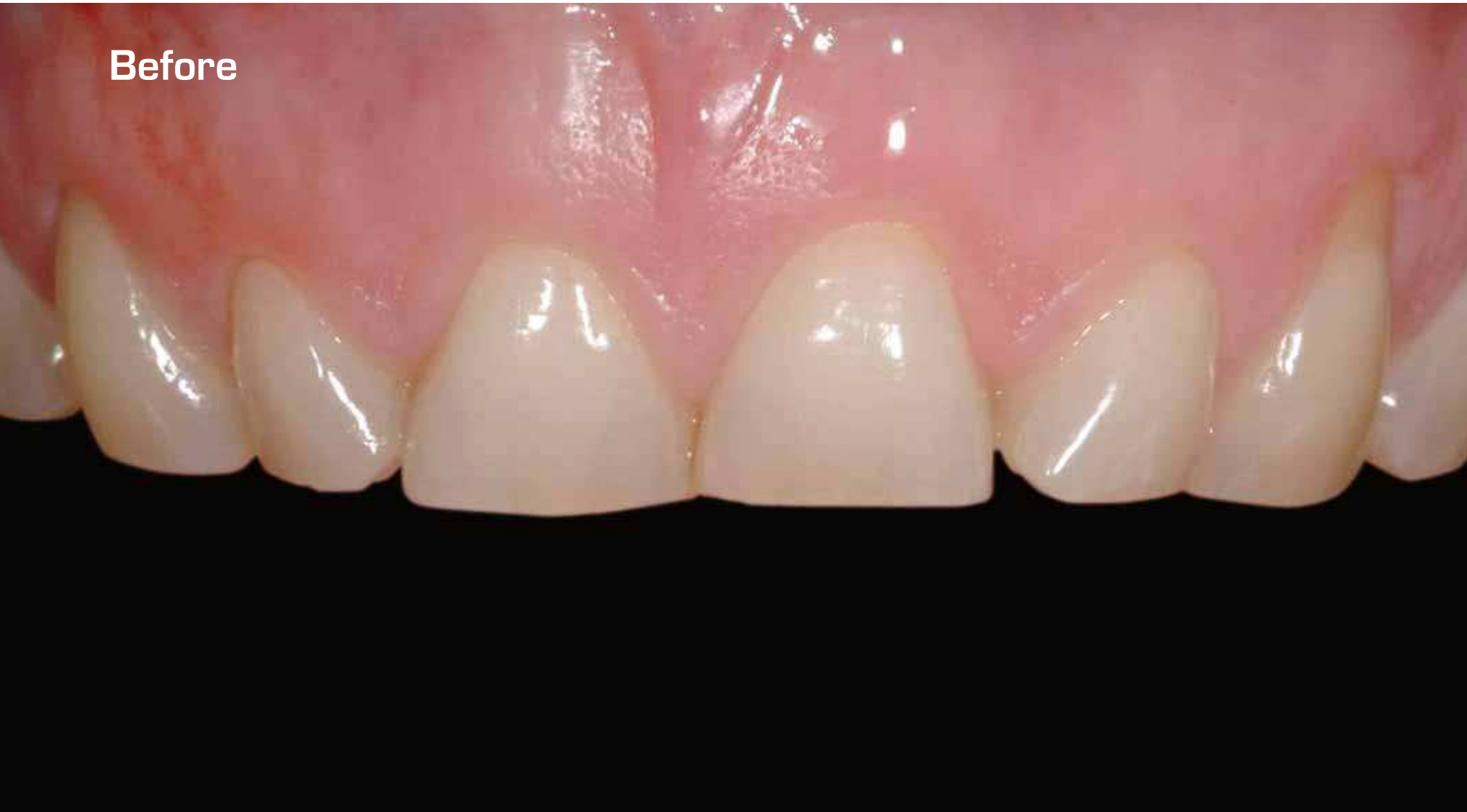

After

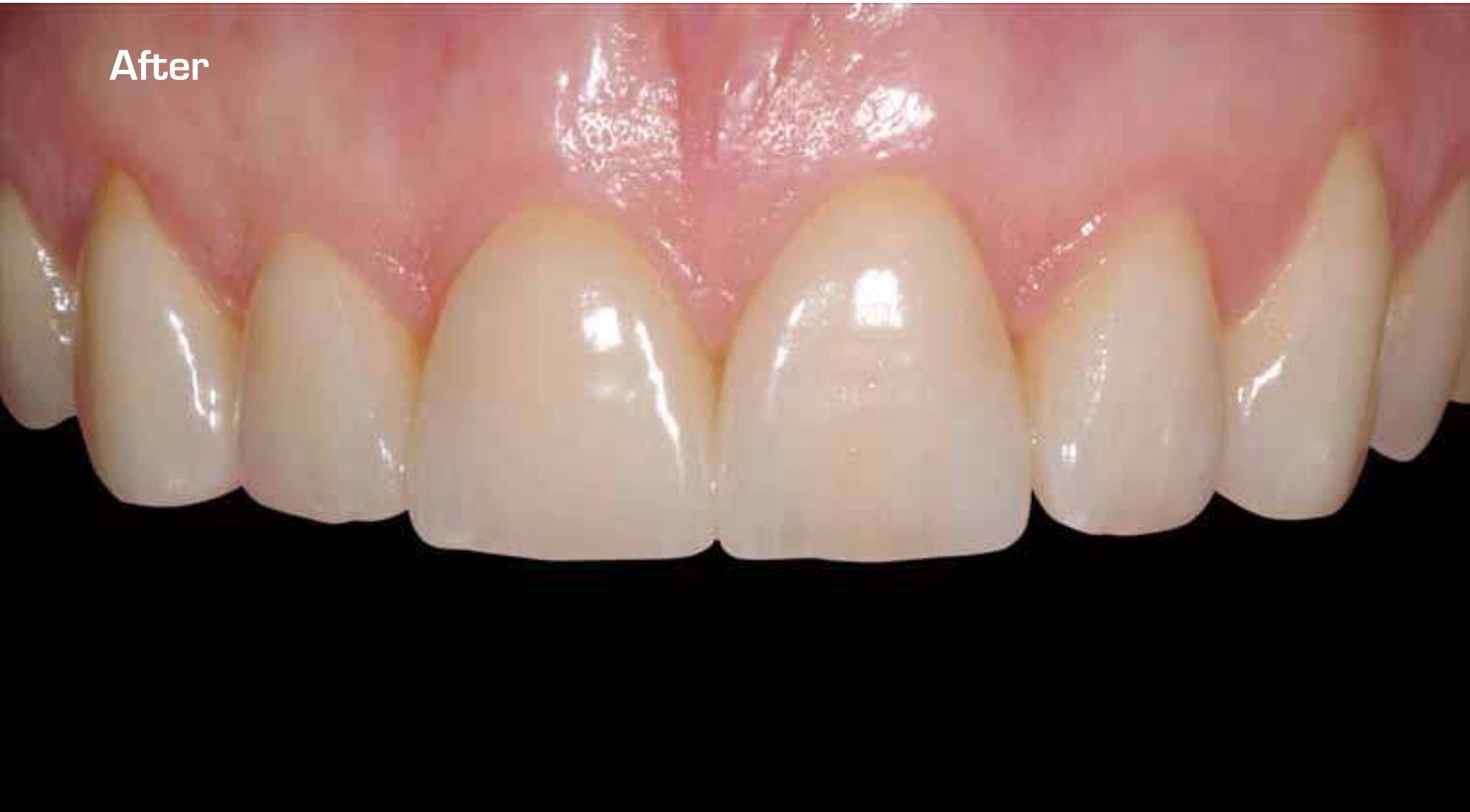



Before



After



## Procera® Crown Alumina

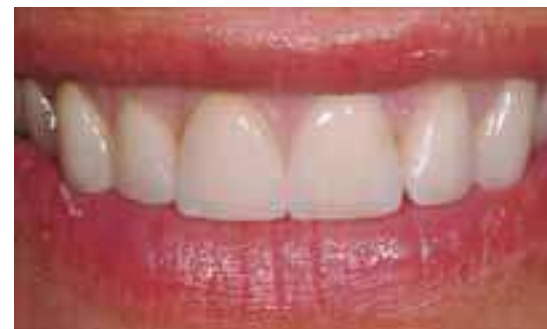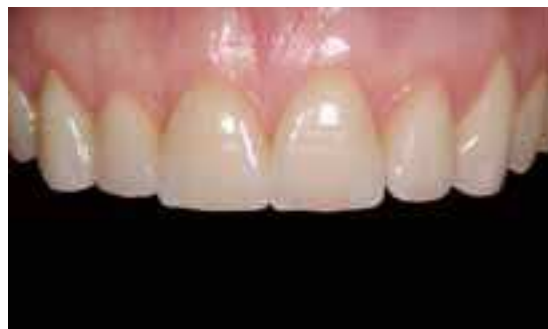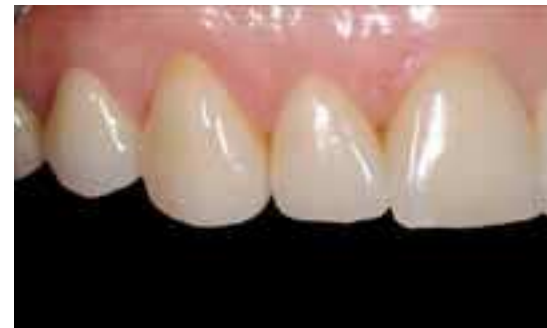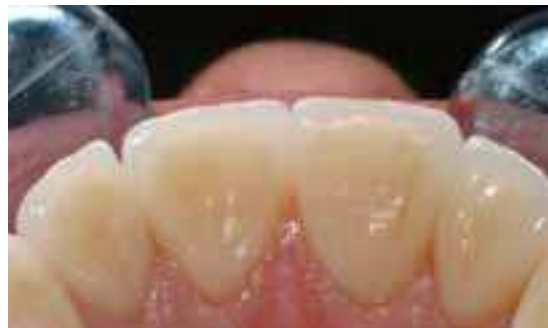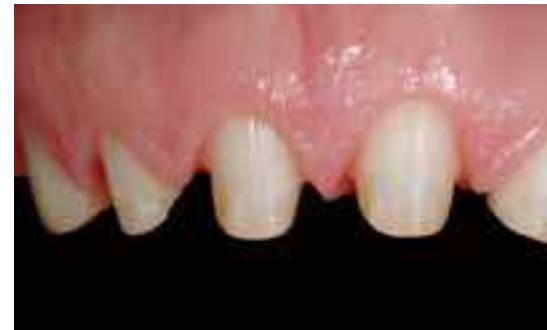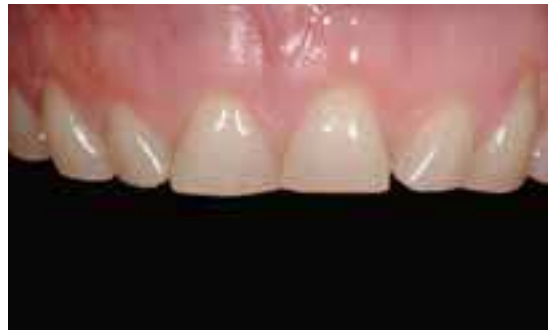Dr. Bernard Touati & Mr. Jean-Marc Etienne, France

This female patient in her 30's presents with heavy incisal abrasion, loss of incisal guidance, phonetic and aesthetic problems.

All preparations are completed on vital teeth, with a peripheral chamfer, the dentin surface is hybridized.

6 Procera® Crown Alumina (0.4 mm copings) were fabricated and cemented with a resin-modified glass-ionomer cement.

Note the soft tissue integration due to the biocompatibility of the restorative material and the excellent light transmission.



## SINGLE TOOTH MISSING/ IMPROVING EXISTING TEETH

## Procera® Crown Alumina

Mr. Ernst A. Hegenbarth, Ms. Dagmar Hildebrandt & Dr. Christoph Meyding, Germany

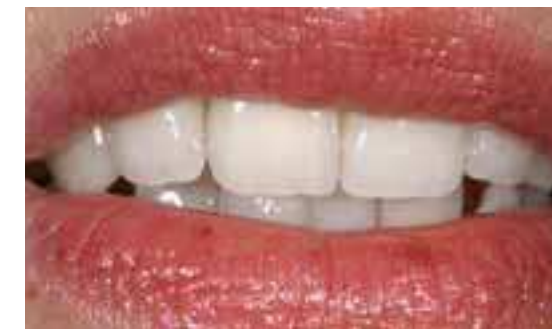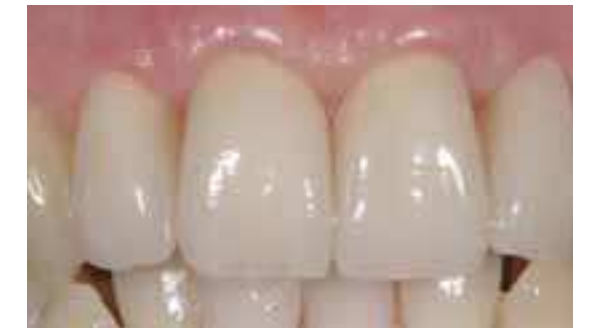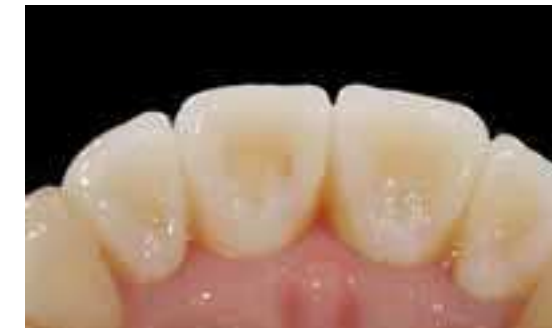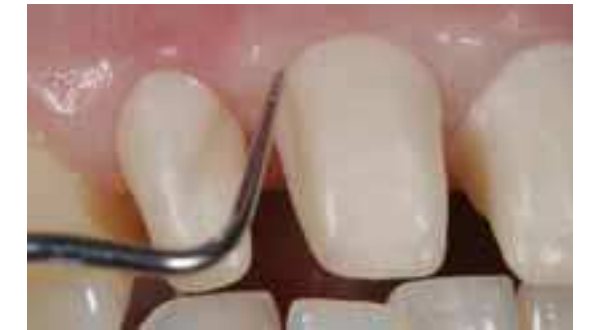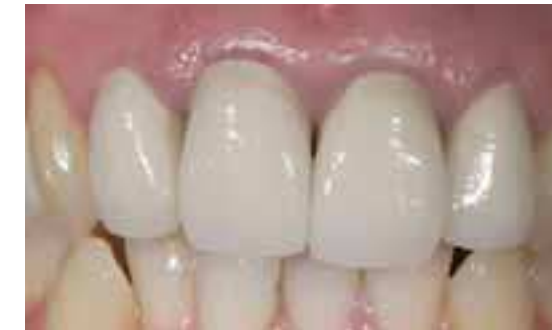The female patient, 38 years old, presented with four existing PFM-Crowns on 12, 11, 21, 22. Her major complaint was the unesthetic appearance of the crowns and the unhealthy, discolored gingiva.

All the crowns showed deficits regarding marginal fit and physiological contour. Due to the interproximal over-counter, the interdental papillae also showed recessions and a low scalloped gingival contour.

The patient wished to replace the crowns with natural-looking, all-ceramic crowns with only very subtle, youthful characterizations.

The 4 Procera® Crown Alumina used were veneered with NobelRondo™ Alumina Ceramics.

In the try-in of the crowns on 12, 11, 21, 22, all aspects of fit, function, form, color and surface texture were evaluated. Due to the detailed esthetic treatment planning, only minor adjustments were necessary.

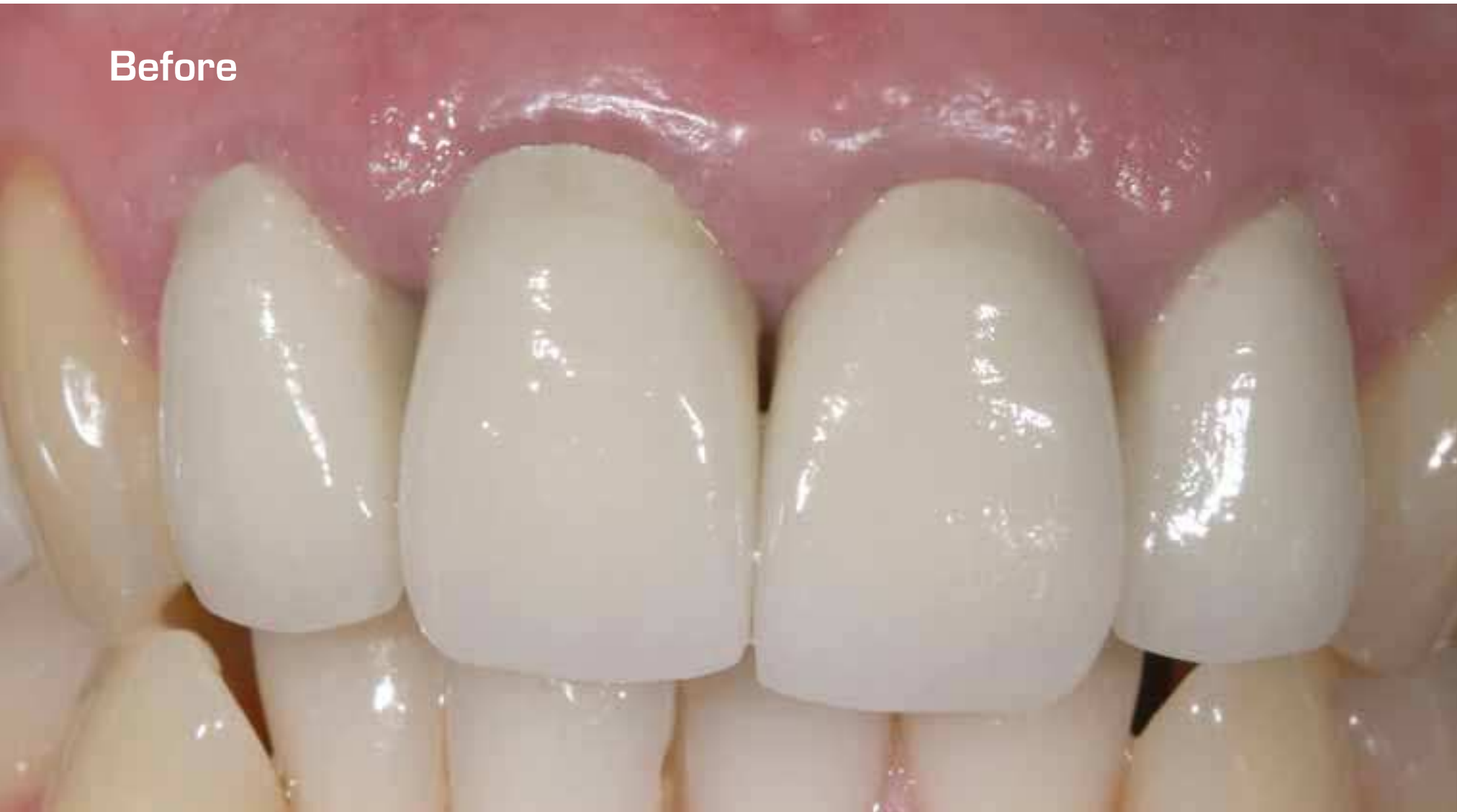

Procera® Crown Alumina

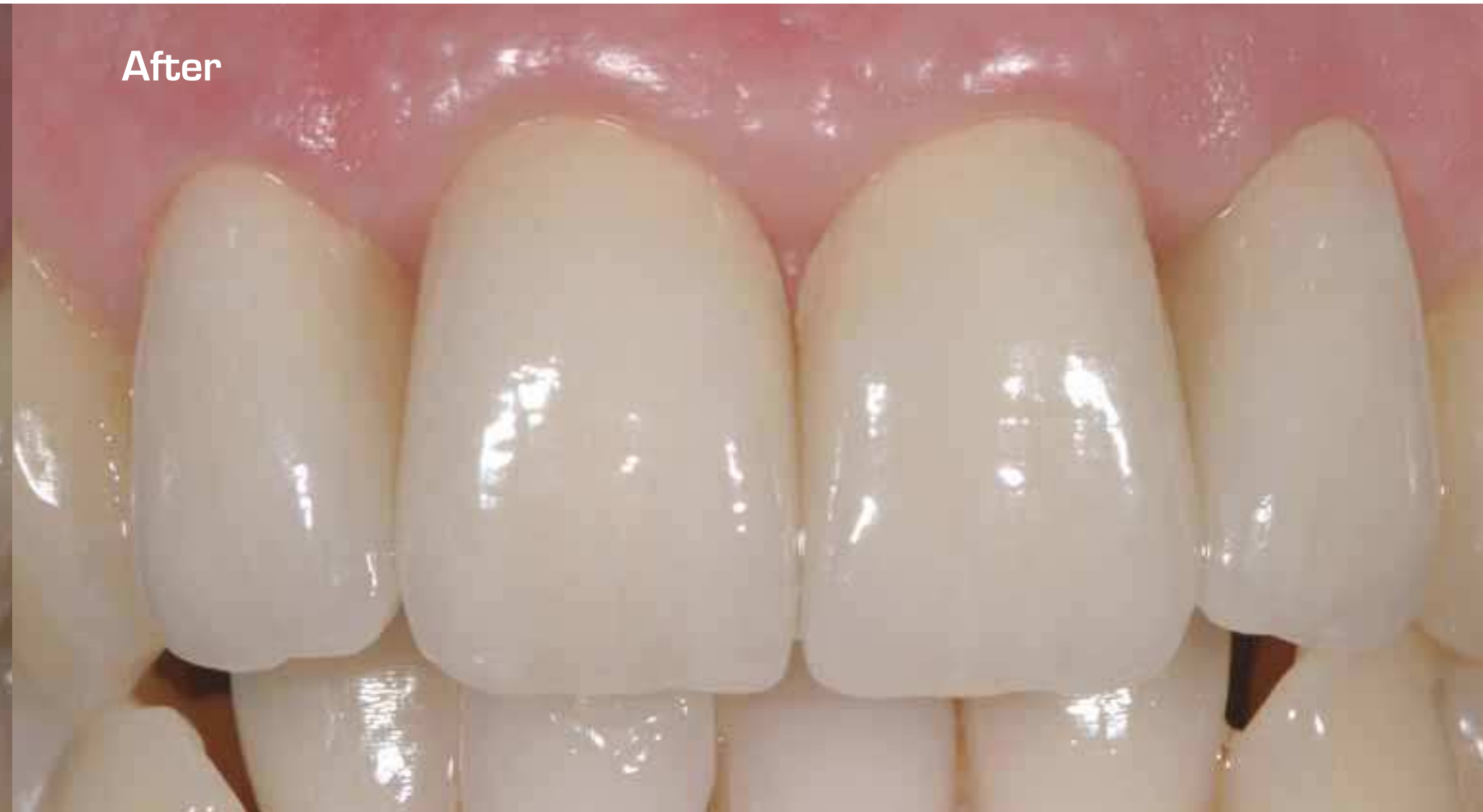Mr. Ernst A. Hegenbarth & Dr. Christoph Meyding, Germany

SINGLE TOOTH MISSING/  
IMPROVING EXISTING TEETH

Before



After



SINGLE TOOTH MISSING/  
IMPROVING EXISTING TEETH



Procera® Bridge Zirconia  
Procera® Crown Zirconia

Dr. Hans Åhlund & Ms. Bodel Sjöholm, Sweden

SINGLE TOOTH MISSING/  
IMPROVING EXISTING TEETH

SINGLE TOOTH MISSING/  
IMPROVING EXISTING TEETH

Before



After



Procera® Bridge Zirconia  
Procera® Crown Zirconia

Dr. Hans Åhlund & Ms. Bodel Sjöholm, Sweden

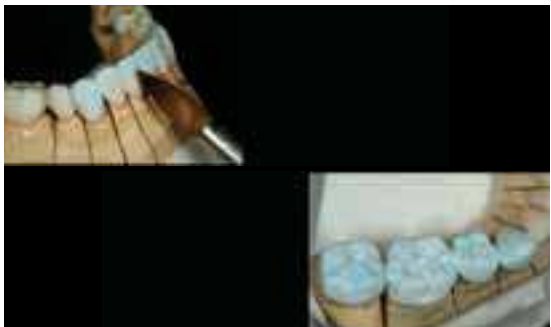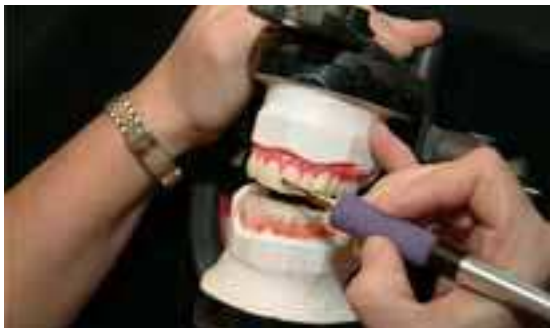Margareta, 64 years old, a complex case including tooth losses, elongated teeth and several teeth subjected to abrasion. As well, she has reduced occlusal height and prosthetic restorations in several different materials. The patient suffers from constant headaches.

Diagnostic Wax-up provides correct smile design and height.

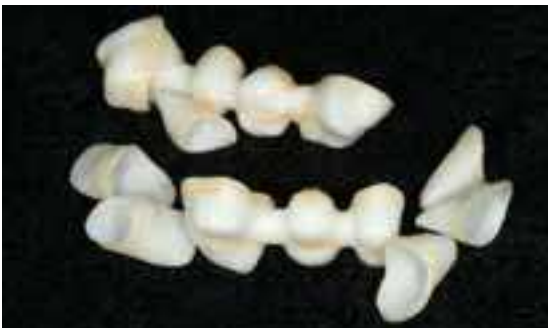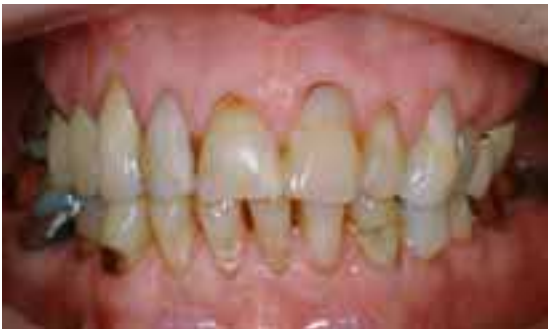We chose the biocompatible and esthetic Procera® Crown and Bridge in zirconia, veneered with NobelRondo™ Zirconia porcelain.

Two 3-unit bridges were produced and in total 27 zirconia units.

A happy patient, looking ten years younger, and with lots of new-found energy.



SINGLE TOOTH MISSING/  
IMPROVING EXISTING TEETH



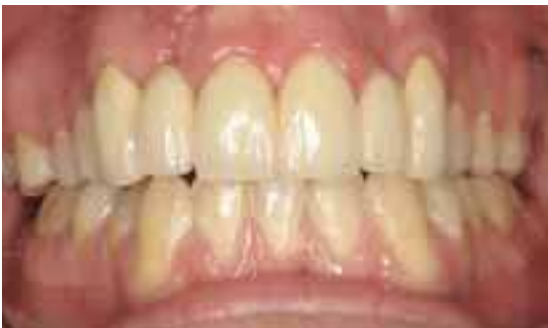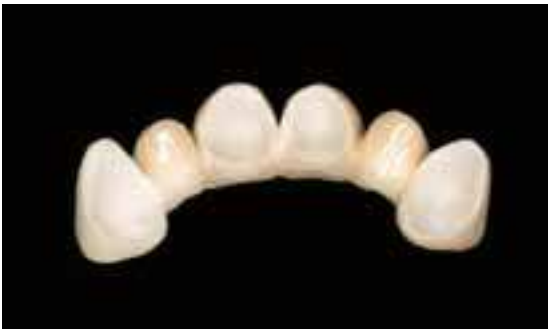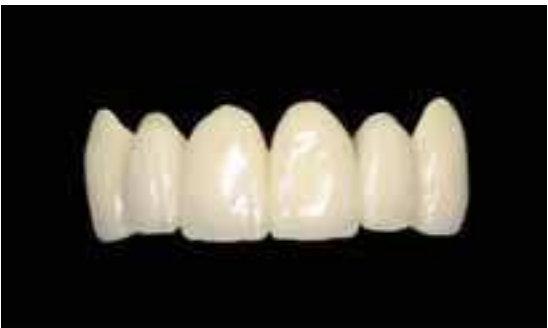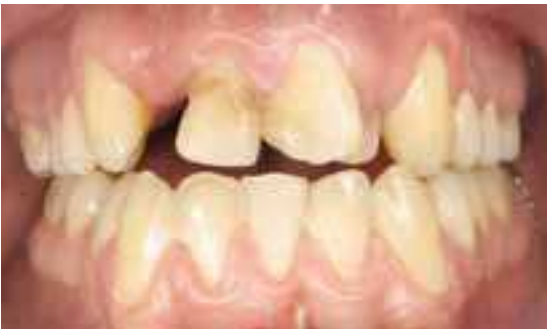Procera® Bridge Zirconia

Dr. Kjell Størksen, Norway

The patient is a 19-year-old boy who has been treated for a cleft lip and palate. The central incisors were hypoplastic and repaired with composite. The left lateral incisor was displaced, endodontically treated and had a very small root. It was extracted, and a full ceramic 6-unit bridge from canine to canine was the treatment of choice. There was not enough bone in the cleft areas to insert implants, and the central incisors needed to be reshaped. By working with temporary crowns, a normal marginal soft tissue line was created.

The final bridge was veneered with NobelRondo™ Zirconia porcelain. Note that the opaque framework does not represent a clinical problem, not even on the canines where the crown is thin on the buccal aspect.

Perhaps it goes without saying that the patient was extremely happy about the final result.



SINGLE TOOTH MISSING/  
IMPROVING EXISTING TEETH



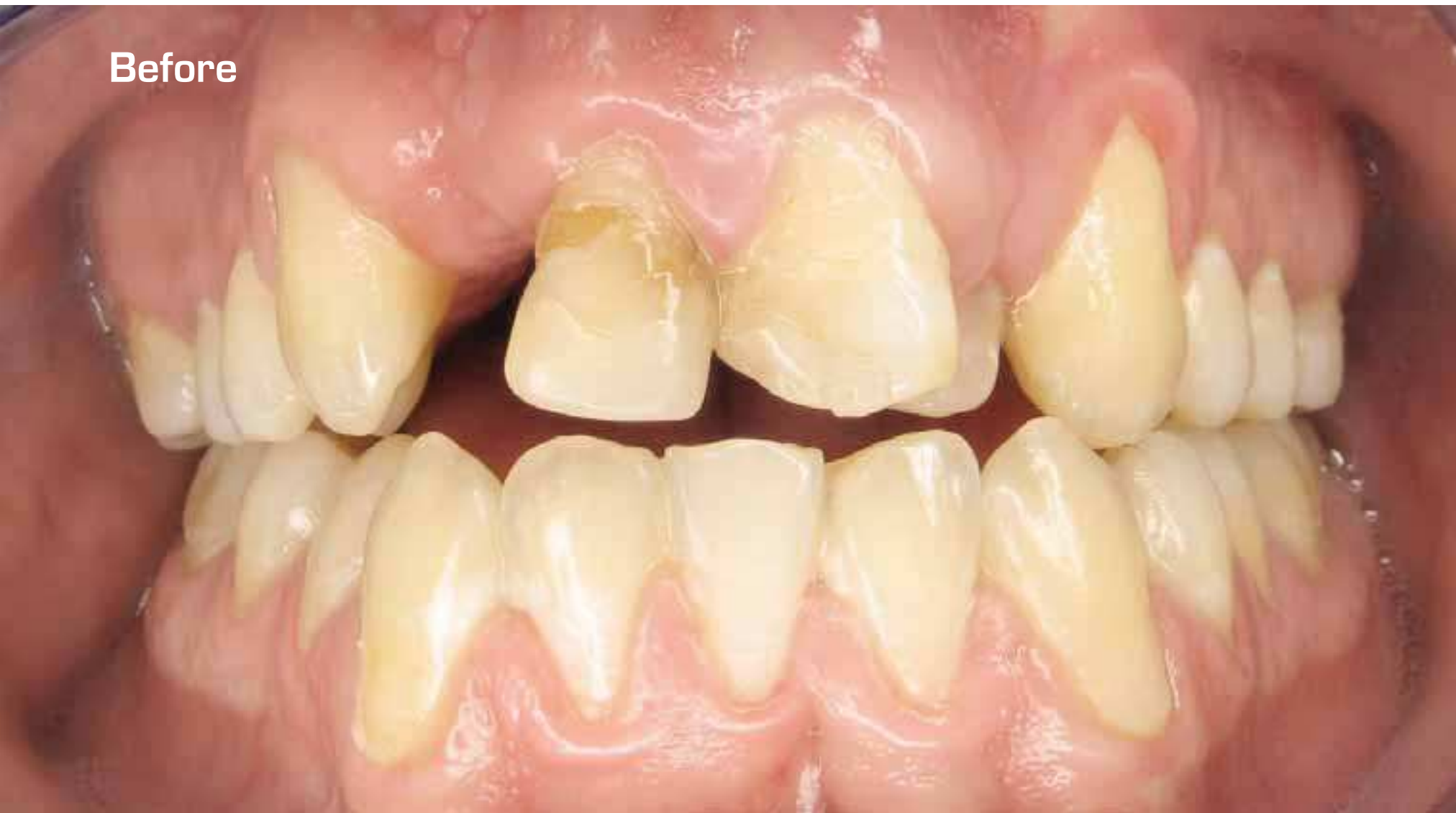Procera® Bridge Zirconia

Dr. Kjell Størksen, Norway

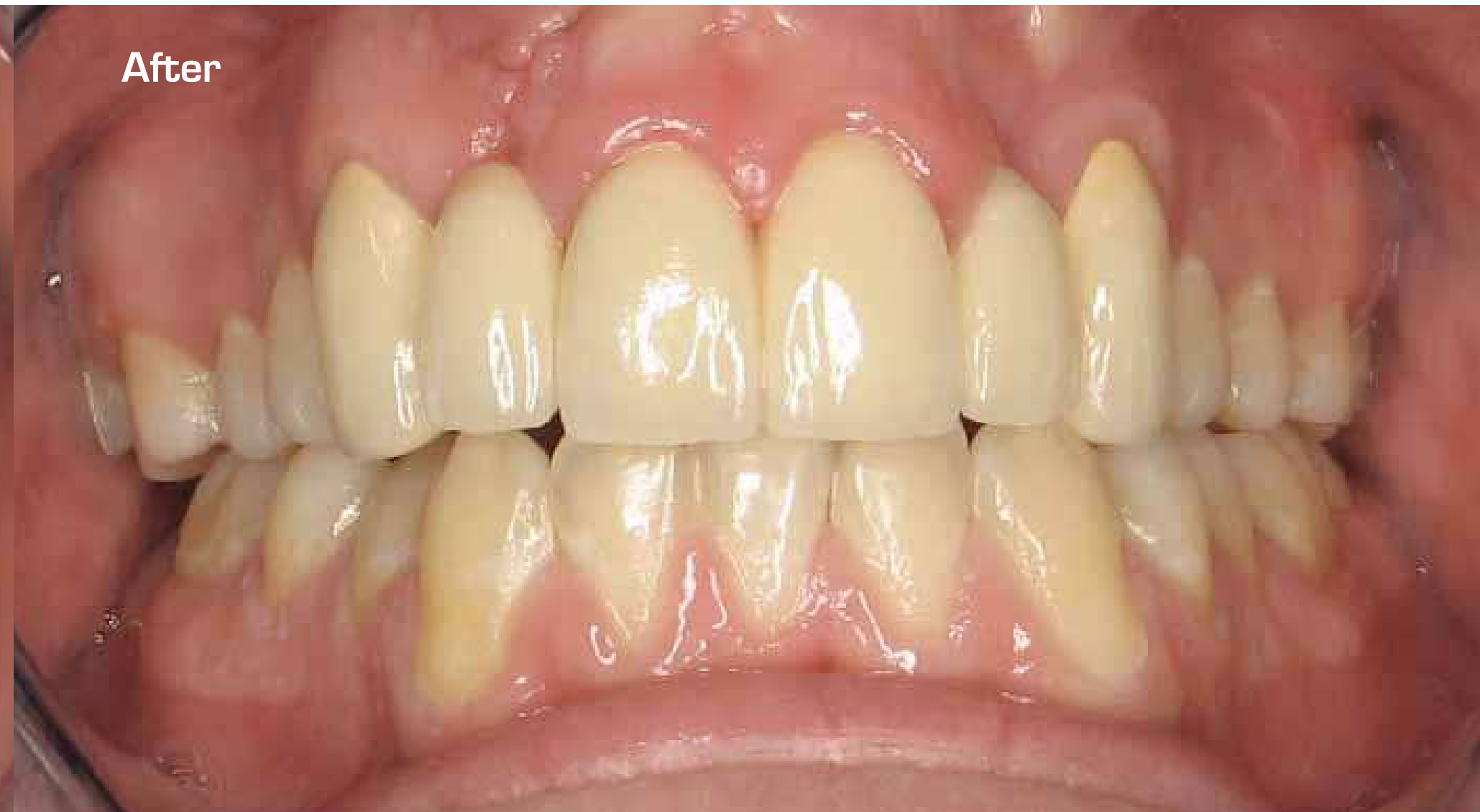SINGLE TOOTH MISSING/  
IMPROVING EXISTING TEETH

SINGLE TOOTH MISSING/  
IMPROVING EXISTING TEETH

Before



After



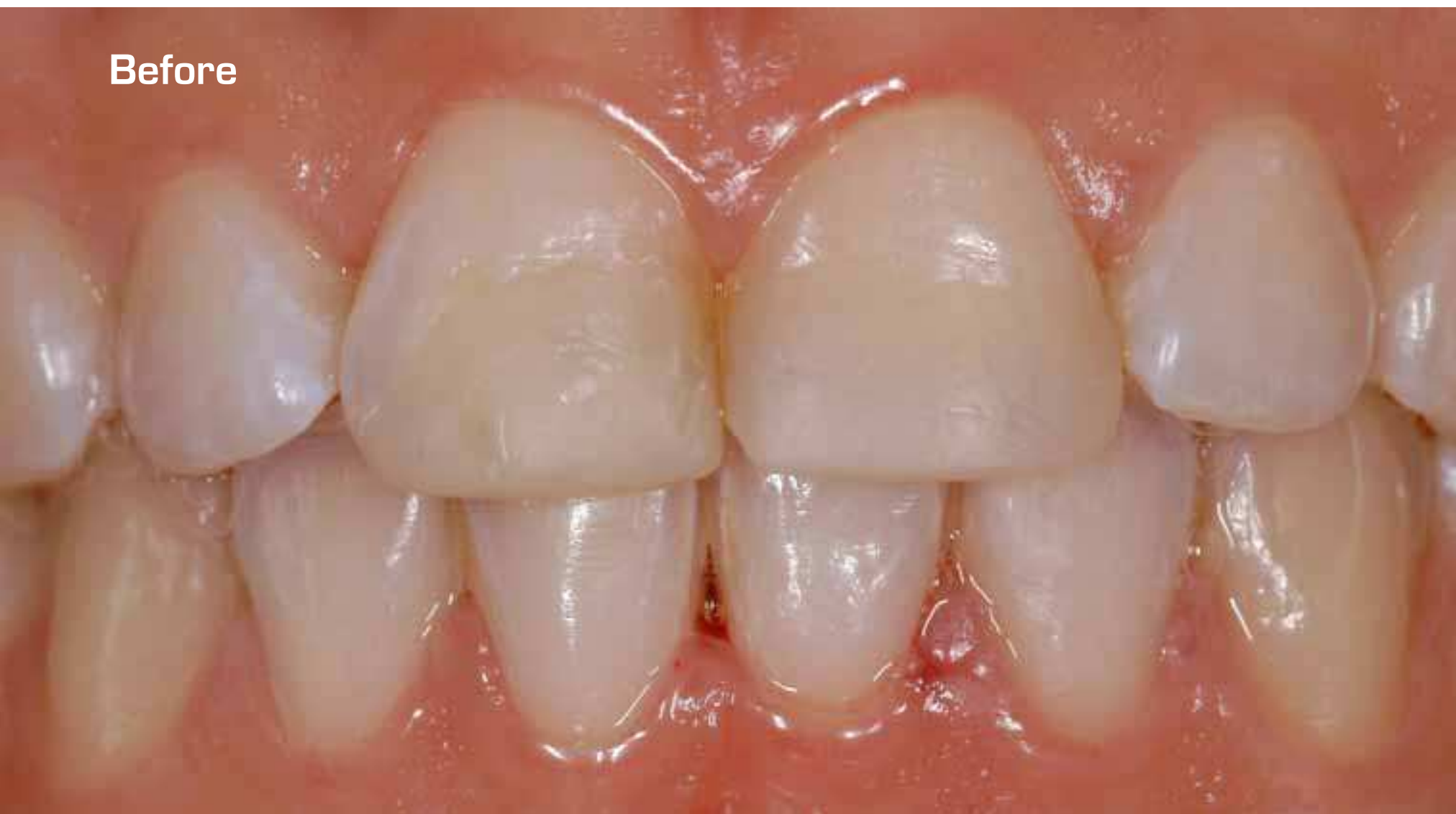

## Procera® Laminate

Dr. Luca Pizzoni, Mr. Davide Riva & Mr. Roberto Dulevio, Italy

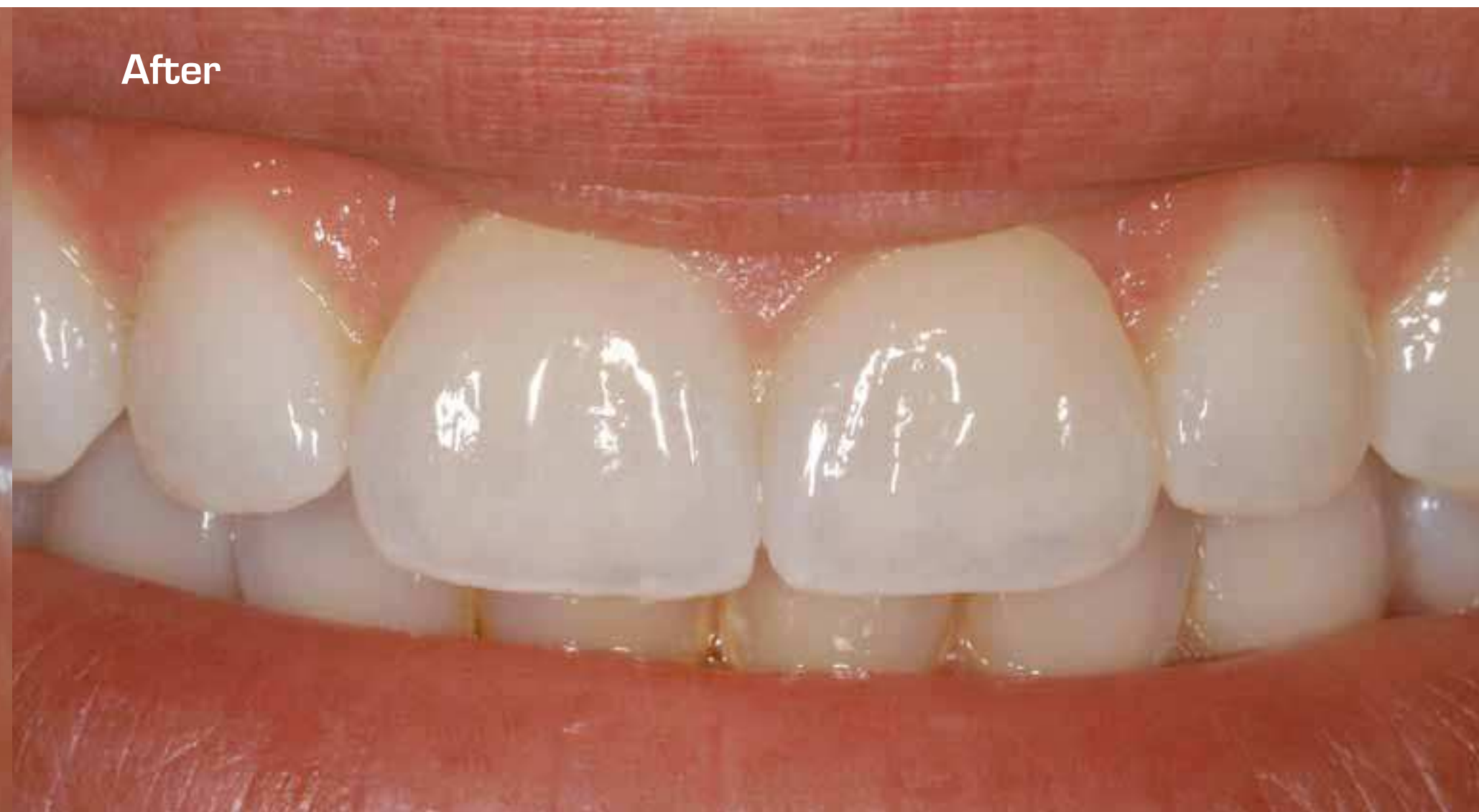SINGLE TOOTH MISSING/  
IMPROVING EXISTING TEETH

Before



56

After



SINGLE TOOTH MISSING/  
IMPROVING EXISTING TEETH

57

# Procera® Laminate

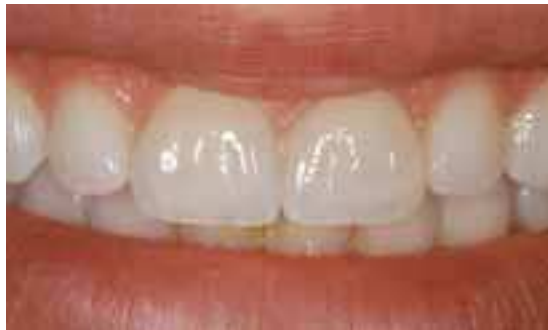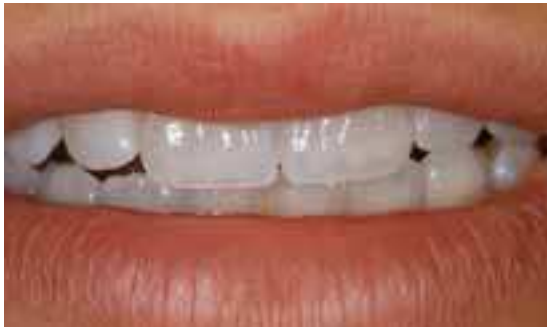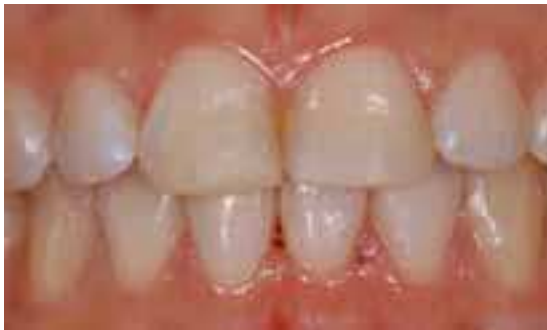Dr. Luca Pizzoni, Mr. Davide Riva & Mr. Roberto Dulevio, Italy

The patient had had a traumatic fracture of her upper central incisors when she was a child.

Composite direct restorations fulfilled her esthetic needs at that time and were a suitable option also to accomplish fixed orthodontic treatment in the teen years.

However her esthetic demands increased and she asked for an improved natural smile.

Since her fractured teeth were vital and enough tooth structure was present, two Procera Laminates became the treatment of choice.



## SINGLE TOOTH MISSING/ IMPROVING EXISTING TEETH

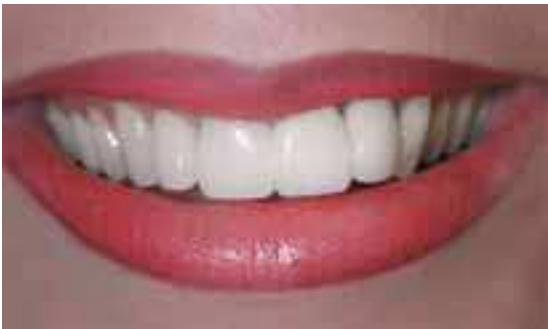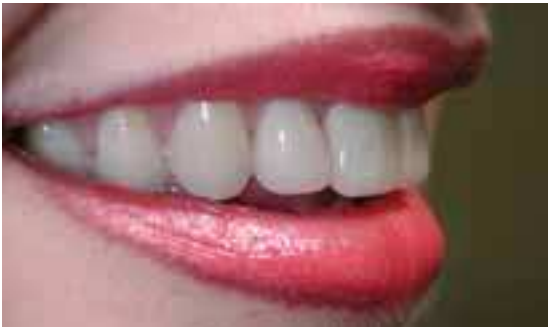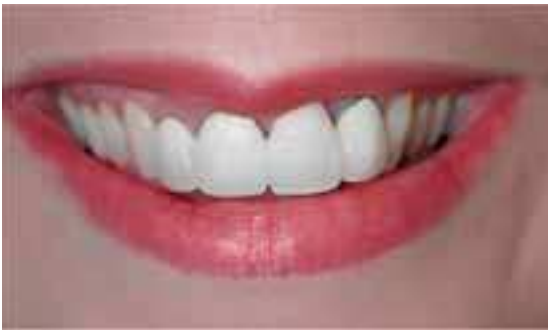# Procera® Crown Alumina Procera® Bridge Alumina

Dr. Peter Van Der Meulen, South Africa

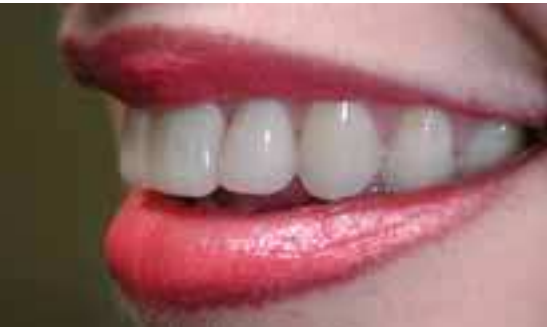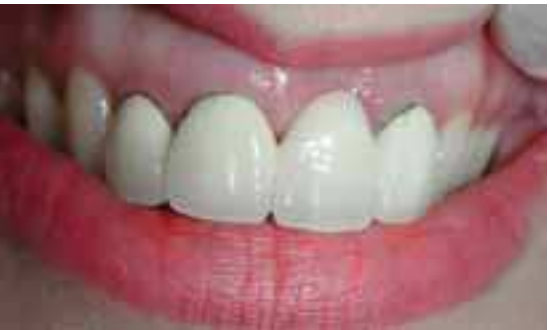Beautiful young lady with severely compromised smile. She had a PFM bridge on 11-22 and a PFM crown on 12.

After root canal treatment, the choice was a Procera® Crown Alumina for 12 and Procera® Bridge Alumina for 11-22 (21 Pontic).

After treatment the young lady showed off her beautiful new teeth in her wonderful smile.

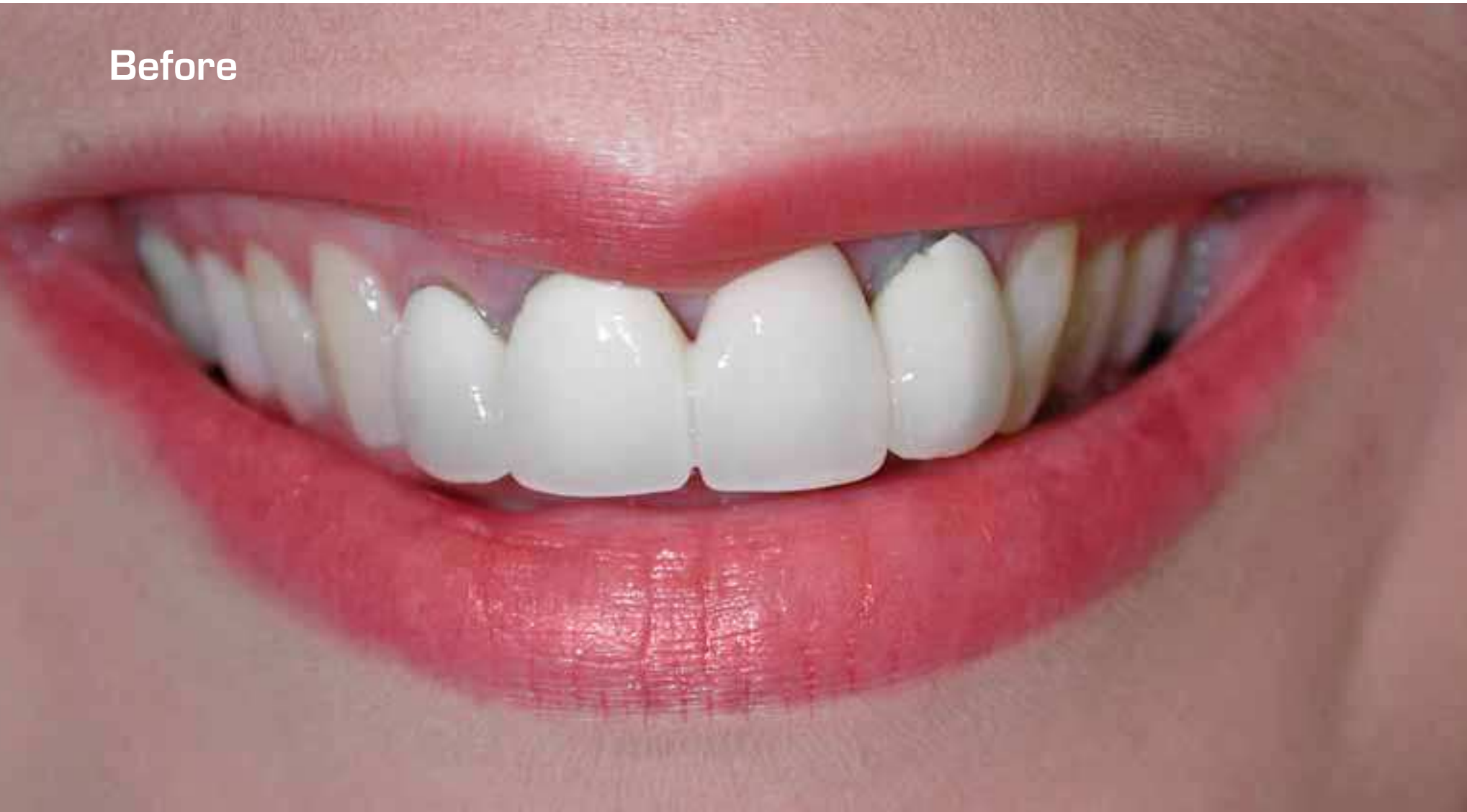

## SINGLE TOOTH MISSING/ IMPROVING EXISTING TEETH

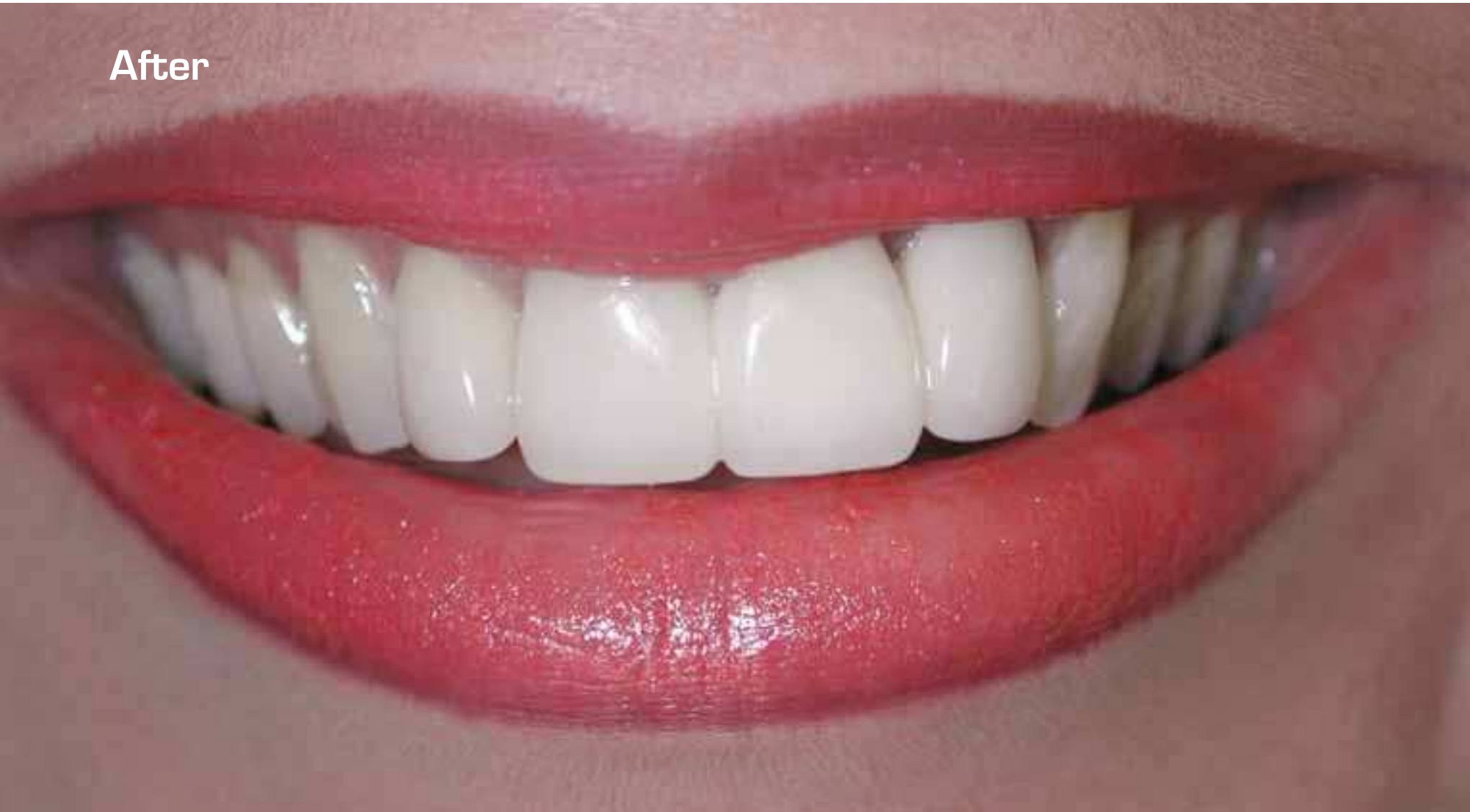



Before



After





# What Doctors Are Saying

“What I like best about Procera® Alumina restorations is that they provide the right balance between opacity and translucency, which allows to achieve great results, both on normal and discolored dentition. With the complete line of Procera® all-ceramic crowns, bridges and laminates, I can offer a high-quality, esthetic solution to most of my patients. The strength and beautiful esthetical appearance, especially of the Procera® Alumina products, is highly appreciated by patients who demand a higher esthetic outcome than what traditional PFM crowns have to offer.”

Dr. Mauro Fradeani, Italy

“Procera® offers me extraordinary flexibility for full coverage in virtually every region of the mouth. In our practice it is the restoration of choice for individual units and many fixed bridge situations. Our patients really like the enhanced esthetics and we are delighted with the consistency of fit and ease of fabrication.”

Dr. Jonathan L Ferencz, USA



Dr. Mauro Fradeani, Italy



Dr. Jonathan L Ferencz, USA

# What Doctors Are Saying

“I believe metal ceramics are obsolete at present for single restorations and short/medium span bridges. Procera® offers me multiple options for all my metal-free prostheses and this versatility is a great asset for any restorative dentist wishing to push the thresholds of his esthetic practice. Procera® helps combine strength, beauty and biocompatibility with the latest technological development.”

Dr. Bernard Touati, France

“The ability to utilize traditional cementation techniques with Procera® is translated into simplified clinical procedures, less post-operative complications and significantly reduced chair time.”

Dr. Eric Van Dooren, Belgium



Dr. Bernard Touati, France



Dr. Eric Van Dooren, Belgium

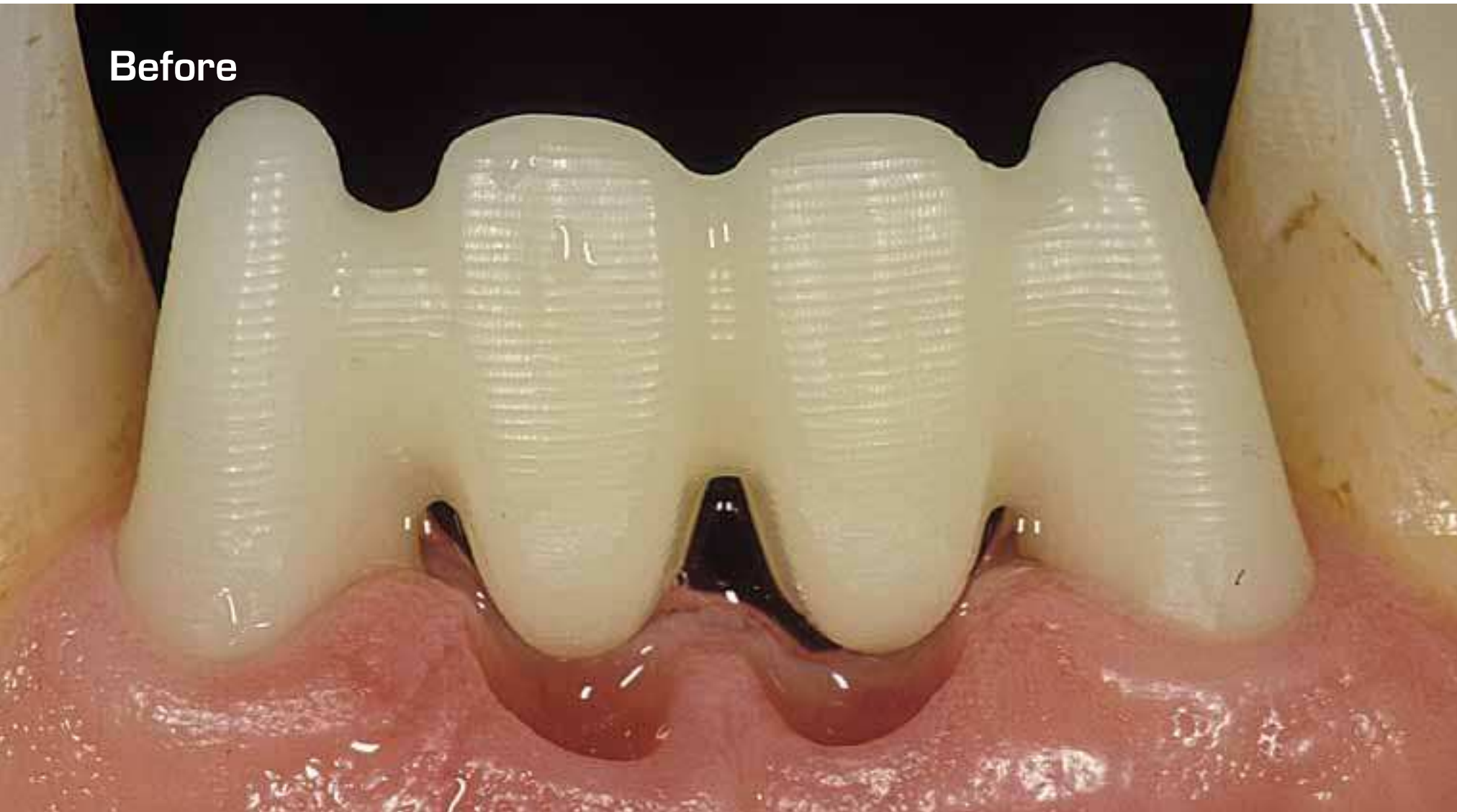
## Several teeth or all teeth missing

Procera® Bridge Alumina

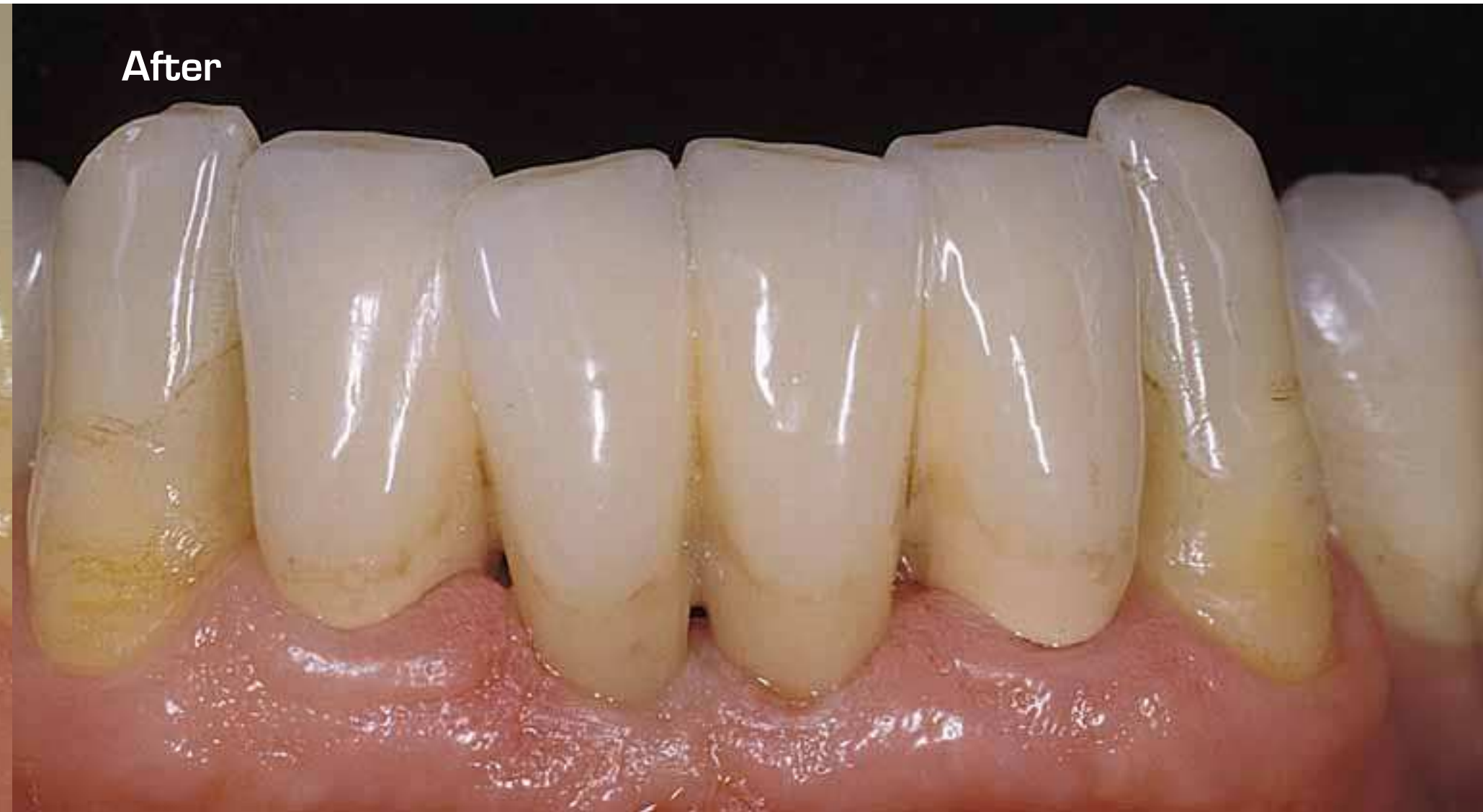Dr. Mauro Fradeani & Mr. Giancarlo Barducci, Italy

SEVERAL TEETH OR  
ALL TEETH MISSING

**Before**



**After**

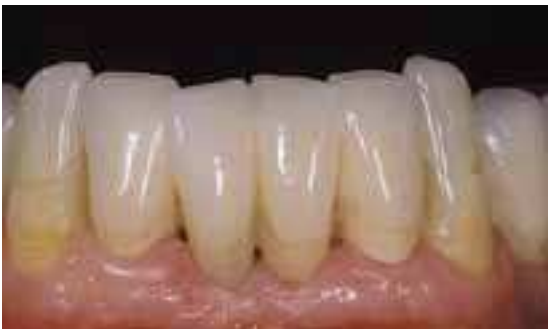
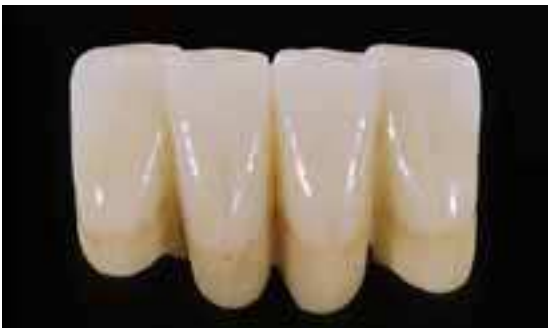
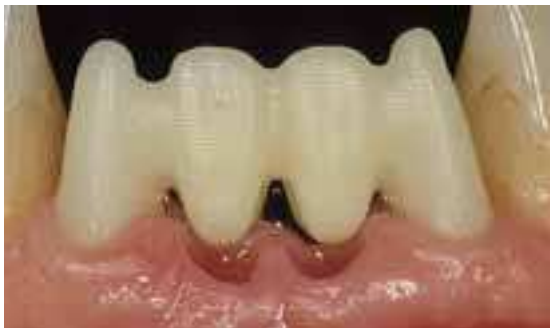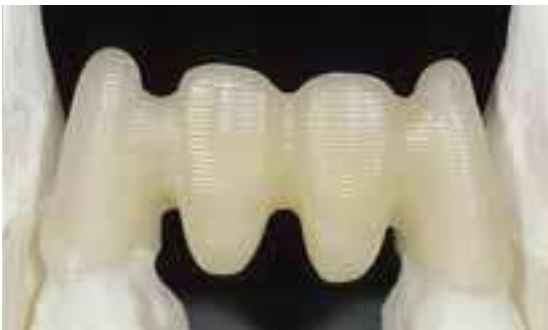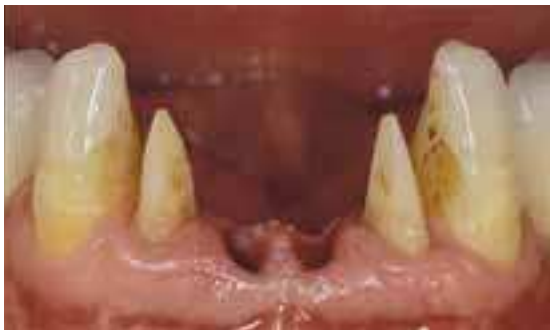# Procera® Bridge Alumina

Dr. Mauro Fradeani & Mr. Giancarlo Barducci, Italy

67-year-old male patient. The two central incisors were extracted and tooth preparation was performed on the lateral incisors.

After the try-in stage of the sub-structure in the patient's mouth, the 4-unit Procera® Bridge Alumina was finalized by using a NobelRondo™ layering ceramic material to fulfill functional and esthetical requests.



SEVERAL TEETH OR  
ALL TEETH MISSING

# Procera® Bridge Zirconia Procera® Abutment Zirconia

Dr. Eric Van Dooren, Belgium

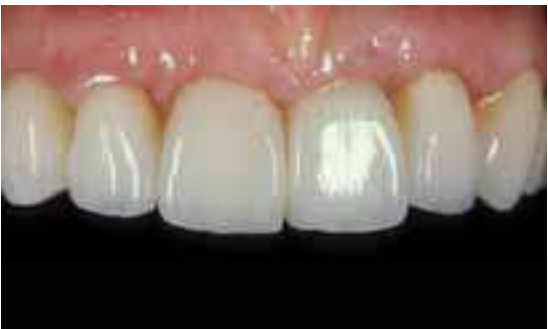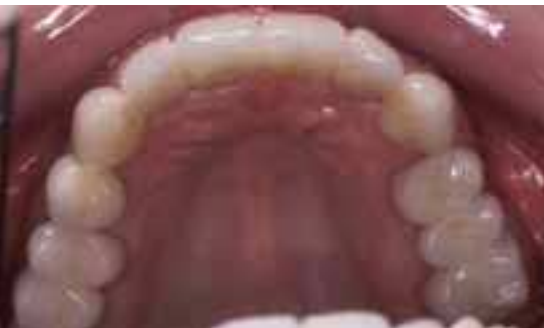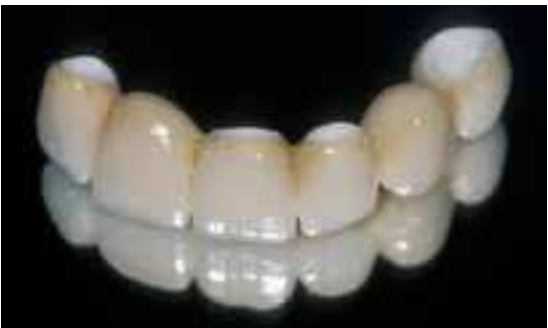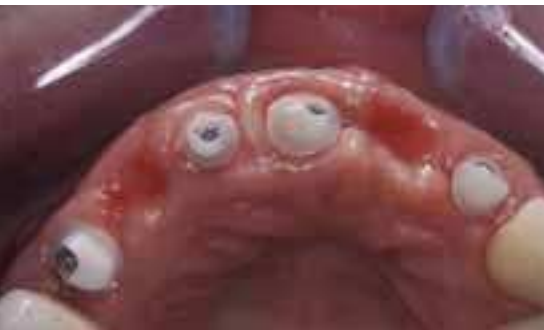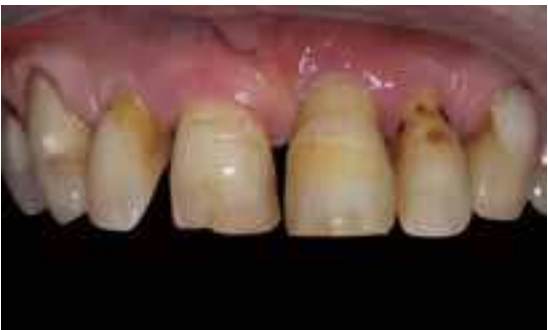60-year-old female patient with advanced periodontal disease, functional and esthetic problems.

Four Procera® Abutment Zirconia was inserted on the implants.

Procera® Bridge Zirconia 6-unit was chosen for this restoration. Please note the pontic design for soft tissue support.

The occlusal view of the restored full upper jaw shows Procera® Crowns and Procera® Bridge cemented on both natural teeth and implants.

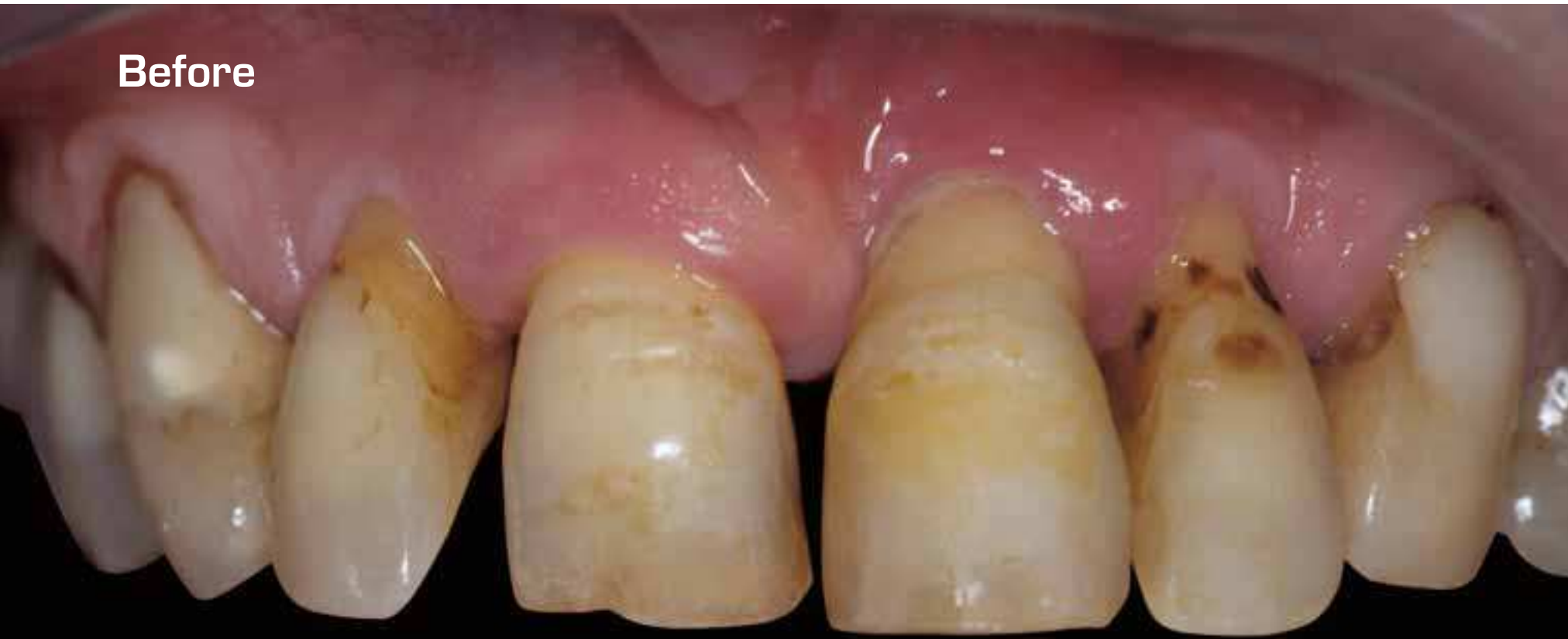Please note the excellent soft tissue integration and the esthetic outcome 3 months after the cementation of the 6-unit anterior bridge.



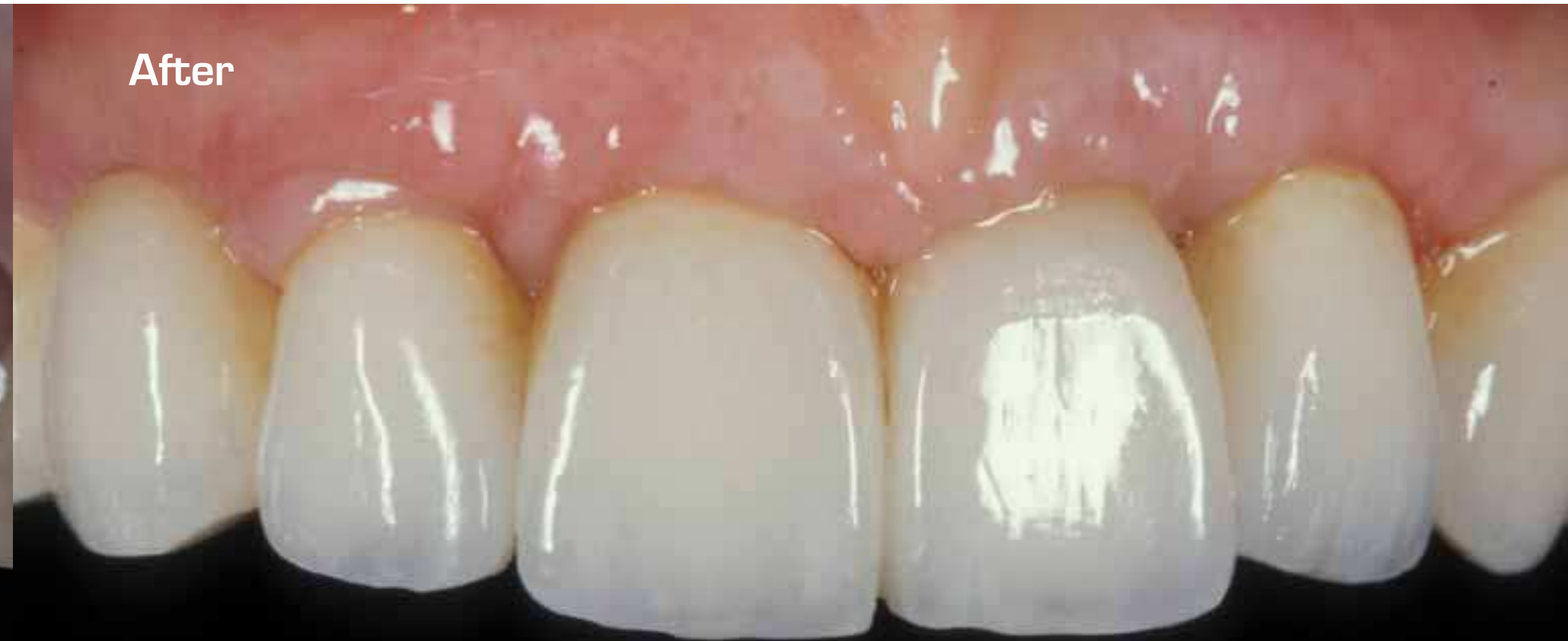SEVERAL TEETH OR  
ALL TEETH MISSING



**Before**



**After**



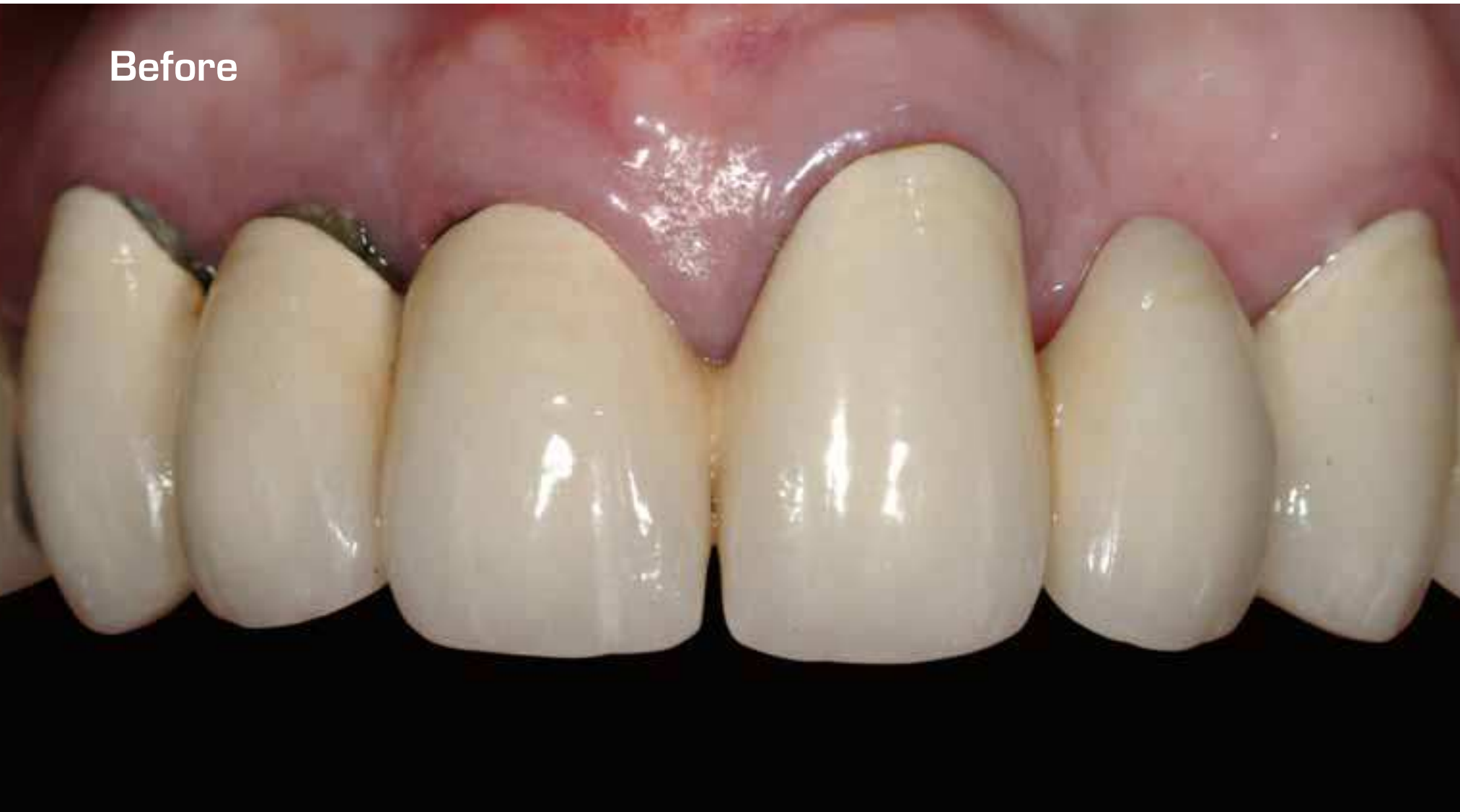## Procera® Implant Bridge Zirconia

Dr. Eric Van Dooren, Belgium

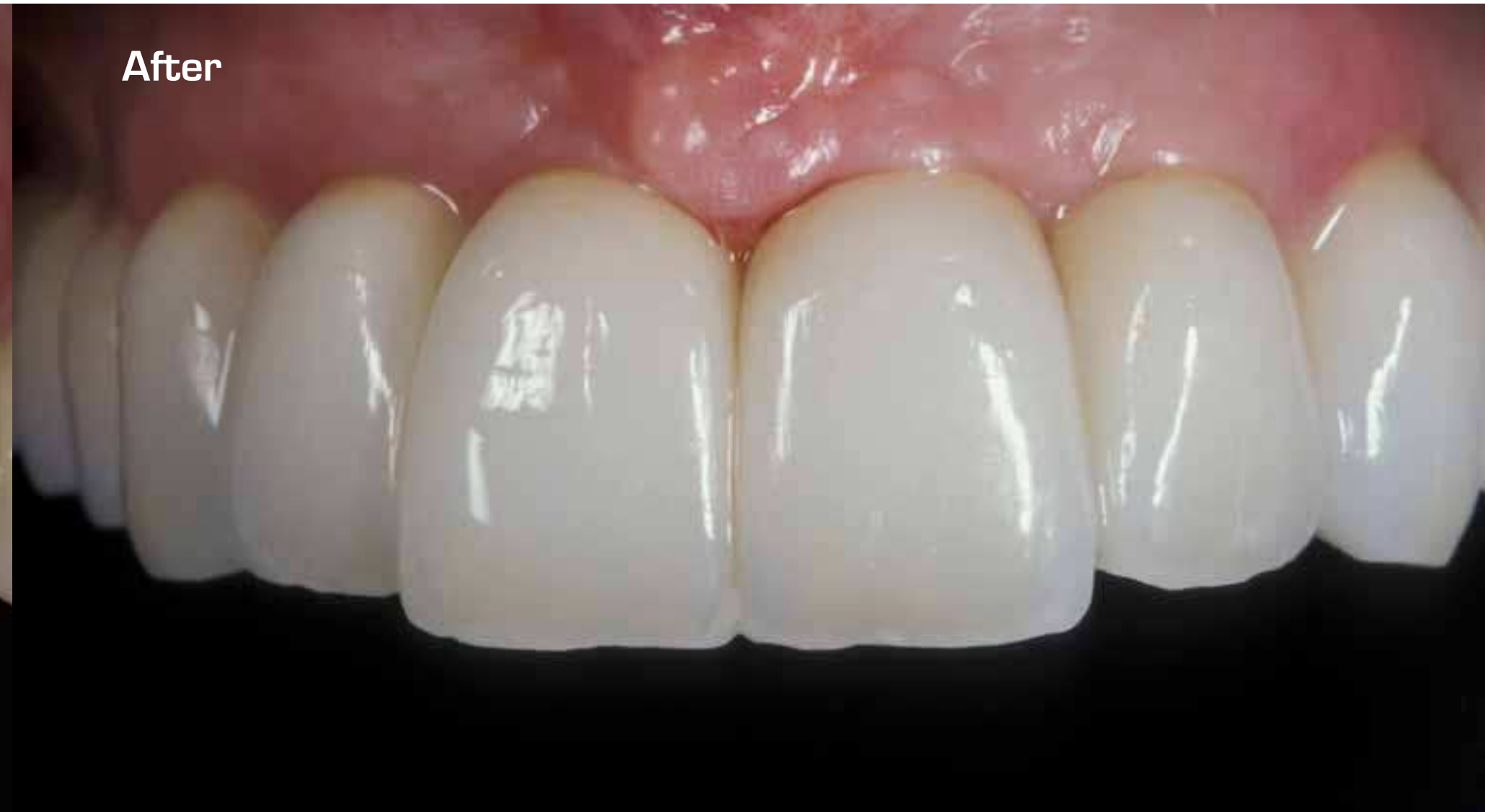SEVERAL TEETH OR  
ALL TEETH MISSING

SEVERAL TEETH OR  
ALL TEETH MISSING

**Before**



**After**



# Procera® Implant Bridge Zirconia

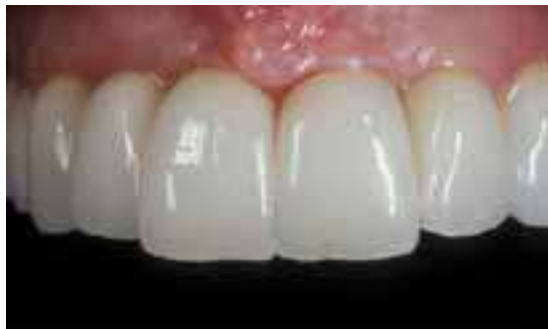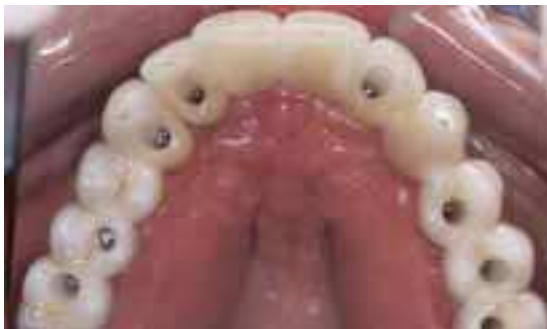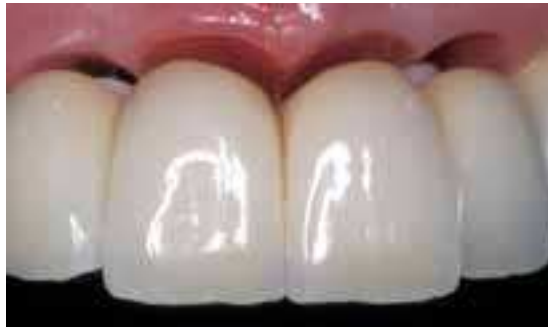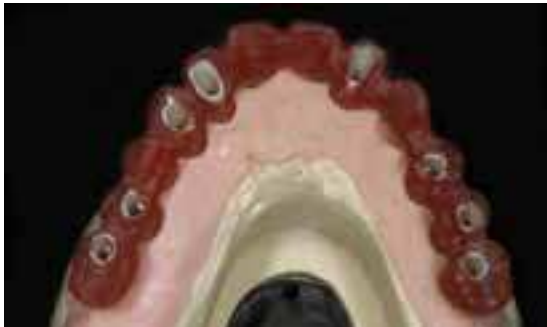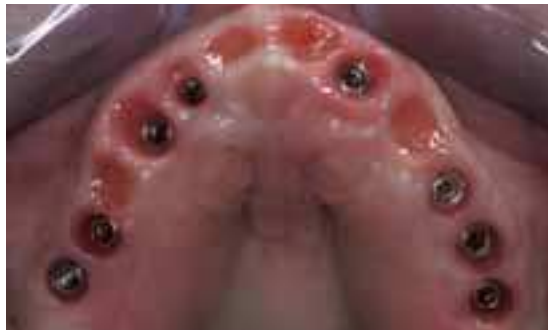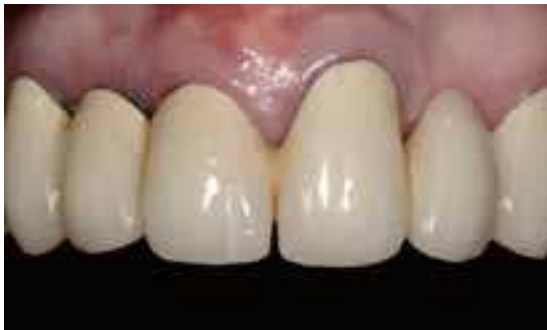Dr. Eric Van Dooren, Belgium

65-year-old female patient with unesthetic restorations and extensive periodontal breakdown combined with recurrent decay.

Implants was inserted with a provi-sionalisation.

For the final restoration Procera® Implant Bridge Zirconia 4-unit and 8-unit was chosen. Please note the soft tissue health and stability.

After 3 months of the placement you can note the excellent soft tissue integration and stability.



SEVERAL TEETH OR  
ALL TEETH MISSING

# Procera® Crown Alumina Procera® Bridge Zirconia Procera® Abutment Zirconia

Mr. Paolo Smaniotto & Dr. Alexander Beikircher, Italy

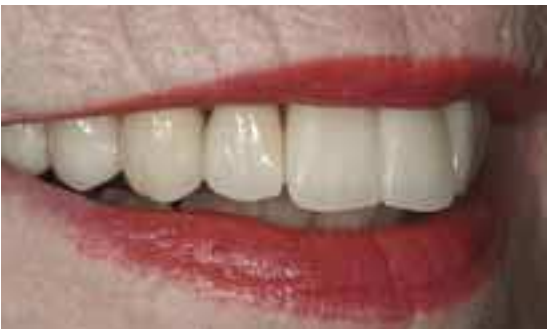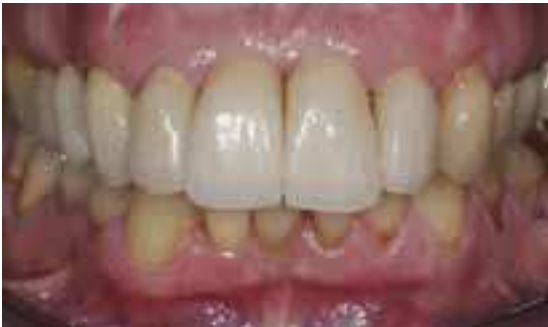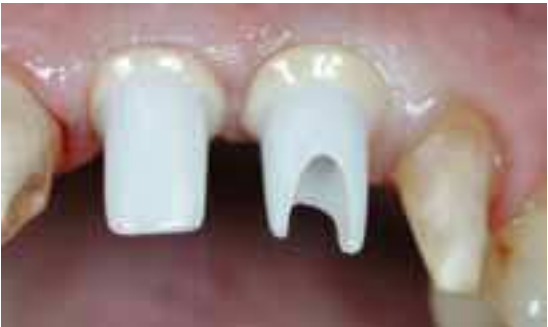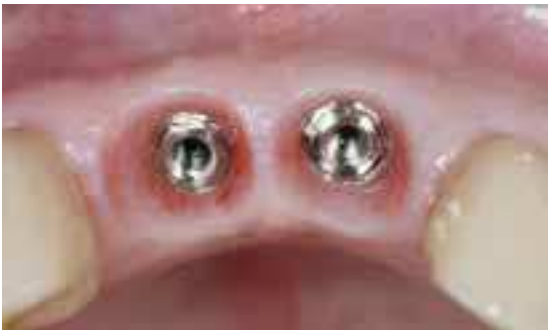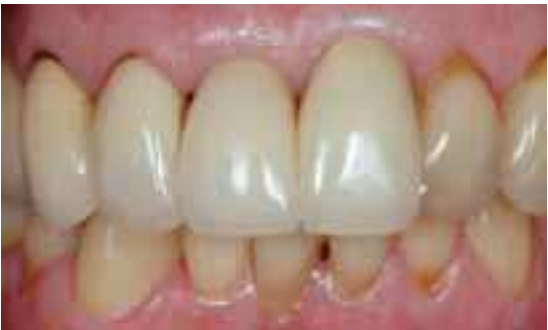Female patient, 73 years old, very active, with a dynamic and youthful image.

The clinical treatment plan is to re-establish the prosthesis of the lost elements 11 and 21 with implants, and to replace the old crowns 12, 11, 21 and 22 and the bridge 13 14 15 16. On the anterior teeth, the old crowns were made with glass-ceramics and, on the posterior, teeth with metal-ceramics.

The bridge chosen was a Procera® Bridge Zirconia, veneered with NobelRondo™ Zirconia porcelain.

The implants on 11 and 21 has individual abutments, Procera® Abutment Zirconia, veneered with NobelRondo™ Zirconia ceramics in individual color.

The single crowns from 12 to 22 is Procera® Crown Alumina and veneered with NobelRondo™ Alumina porcelain.



SEVERAL TEETH OR  
ALL TEETH MISSING

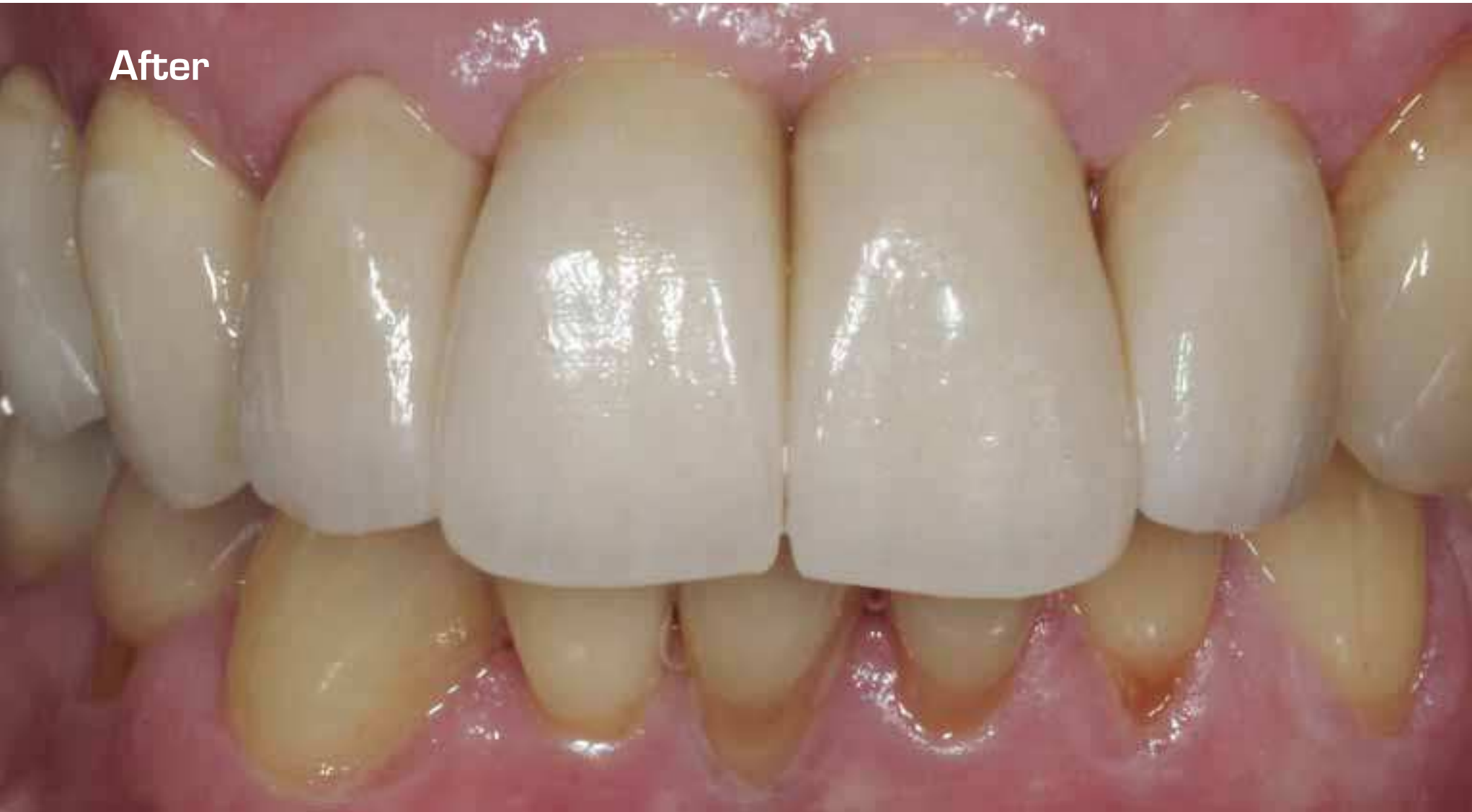
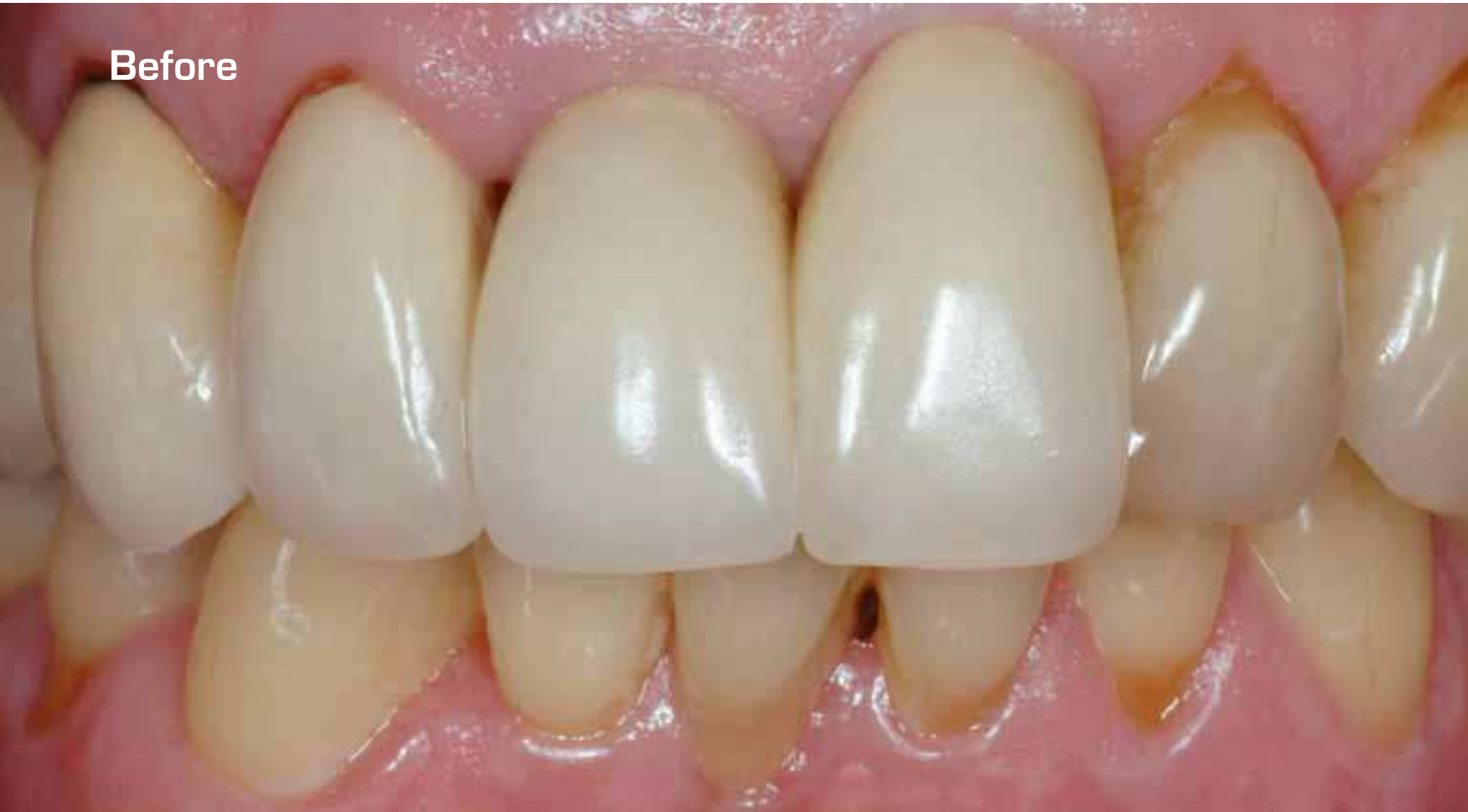
Procera® Crown Alumina  
Procera® Bridge Zirconia  
Procera® Abutment Zirconia

Mr. Paolo Smaniotto & Dr. Alexander Beikircher, Italy

SEVERAL TEETH OR  
ALL TEETH MISSING

SEVERAL TEETH OR  
ALL TEETH MISSING

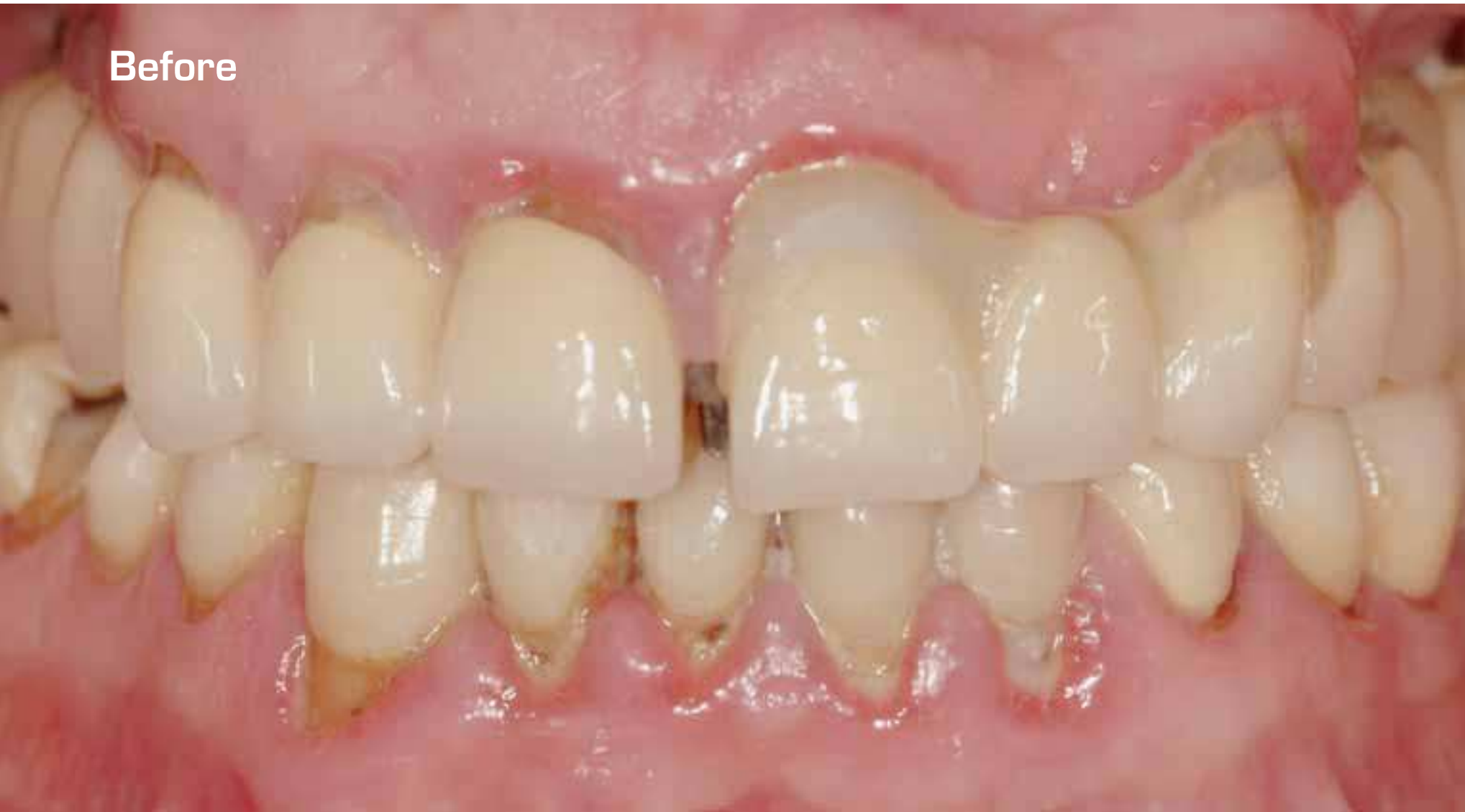

Procera® Abutment Zirconia  
Procera® Crown Alumina  
Procera® Crown Zirconia  
Dr. Iñaki Gamborena, Spain

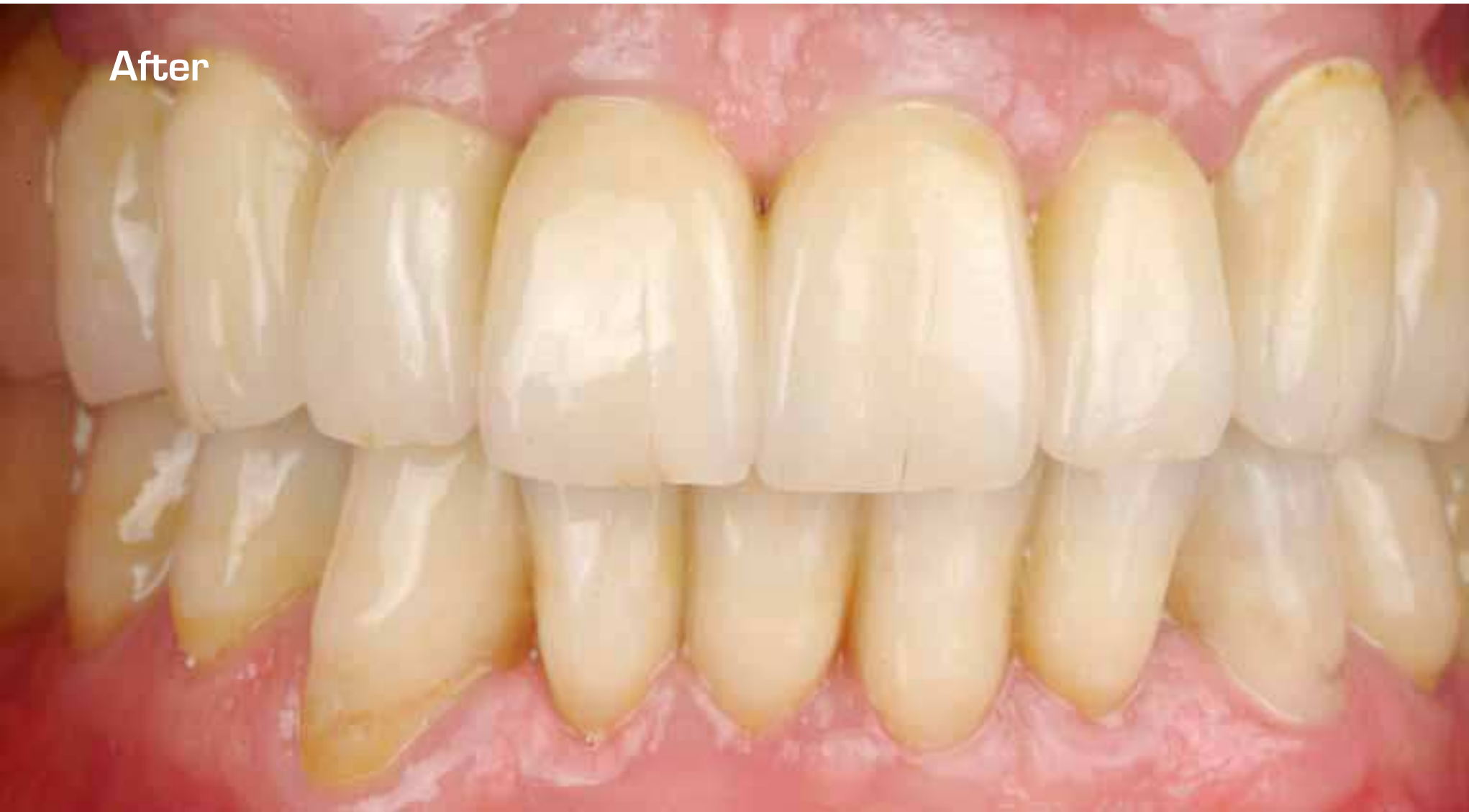SEVERAL TEETH OR  
ALL TEETH MISSING

SEVERAL TEETH OR  
ALL TEETH MISSING

Before



After



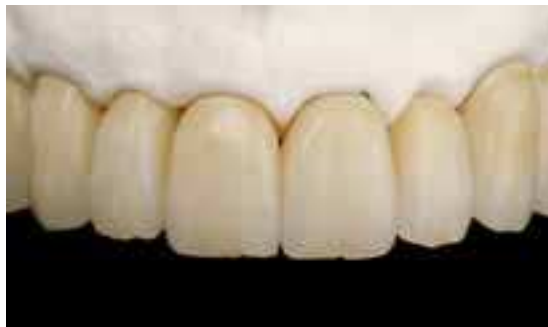
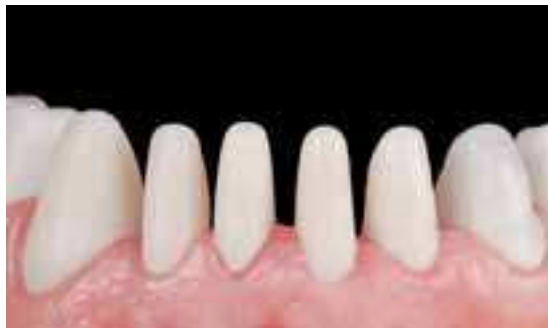
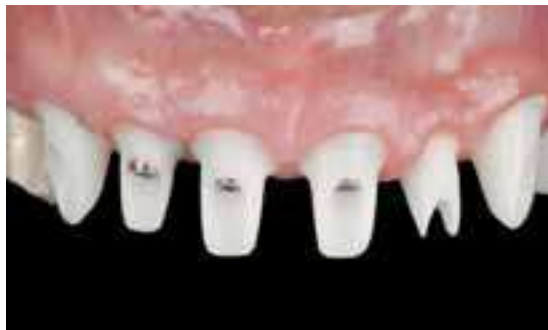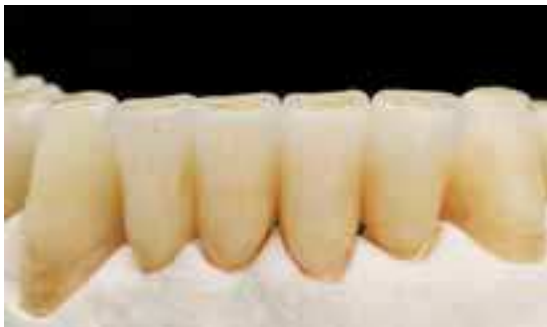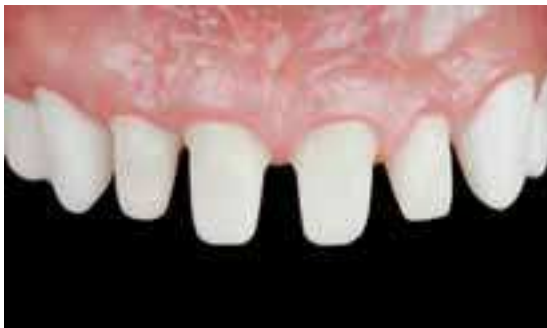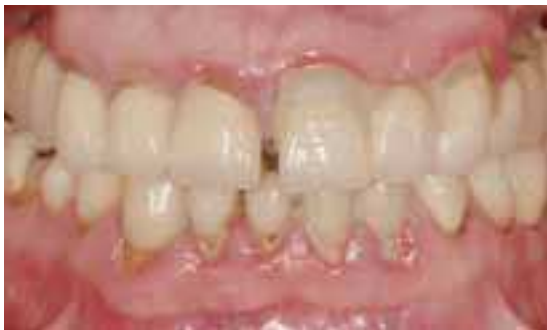Procera® Abutment Zirconia  
Procera® Crown Alumina  
Procera® Crown Zirconia

Dr. Iñaki Gamborena, Spain

Male patient presented with failing full mouth rehabilitation performed only few years earlier. Front upper teeth were broken to the gum line, as well as broken attachment between the two central incisors. Big functional and periodontal problems needed to be addressed before planning active treatment.

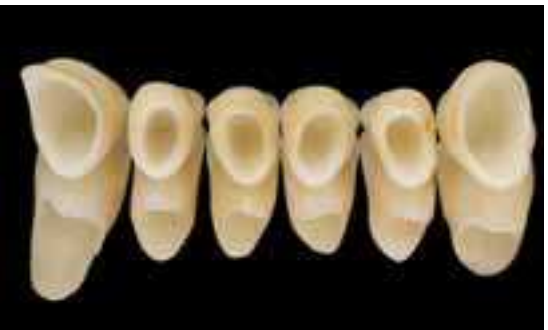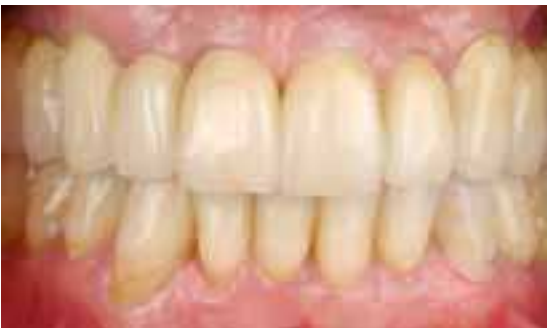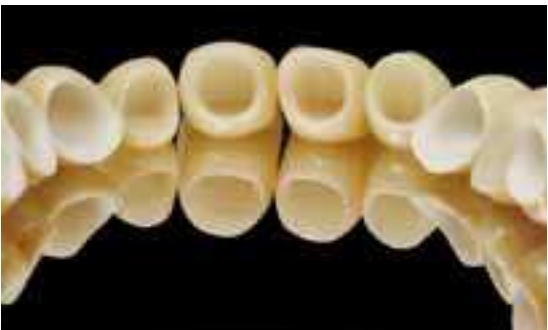In a second phase, multiple immediate implant placement were performed on the entire maxilla and conventional crowns on the mandible.



SEVERAL TEETH OR  
ALL TEETH MISSING

Besides the complexity of the case, our challenge was to restore this case with maximum esthetics as well as presenting a complete, comprehensive and predictable system for implant abutments, single crown and even multiple unit restorations.

The products chosen were Procera® Abutment Zirconia and Procera® Crown Alumina and Zirconia. Notice the optimal high esthetic results achieved with these restorations.



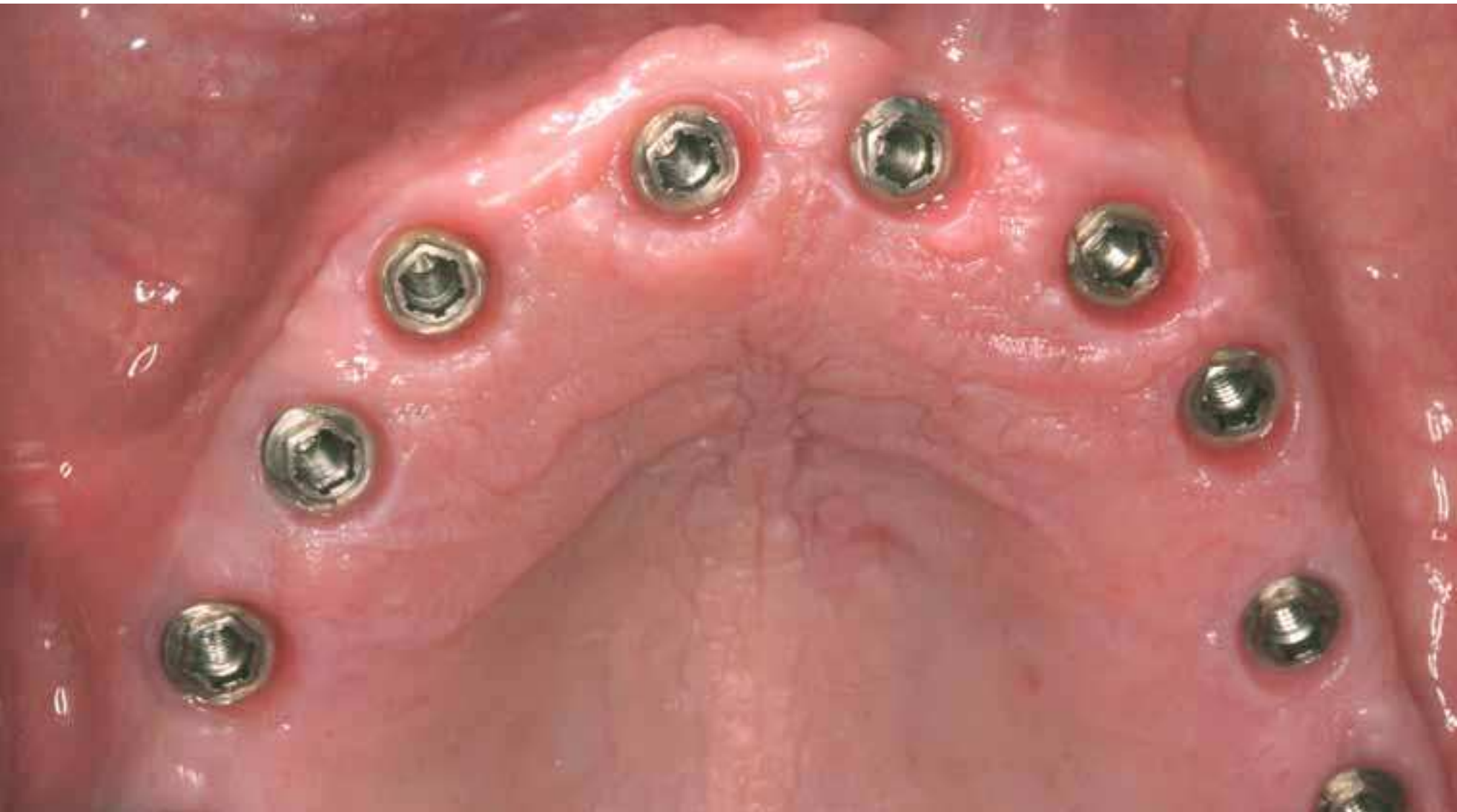SEVERAL TEETH OR  
ALL TEETH MISSING



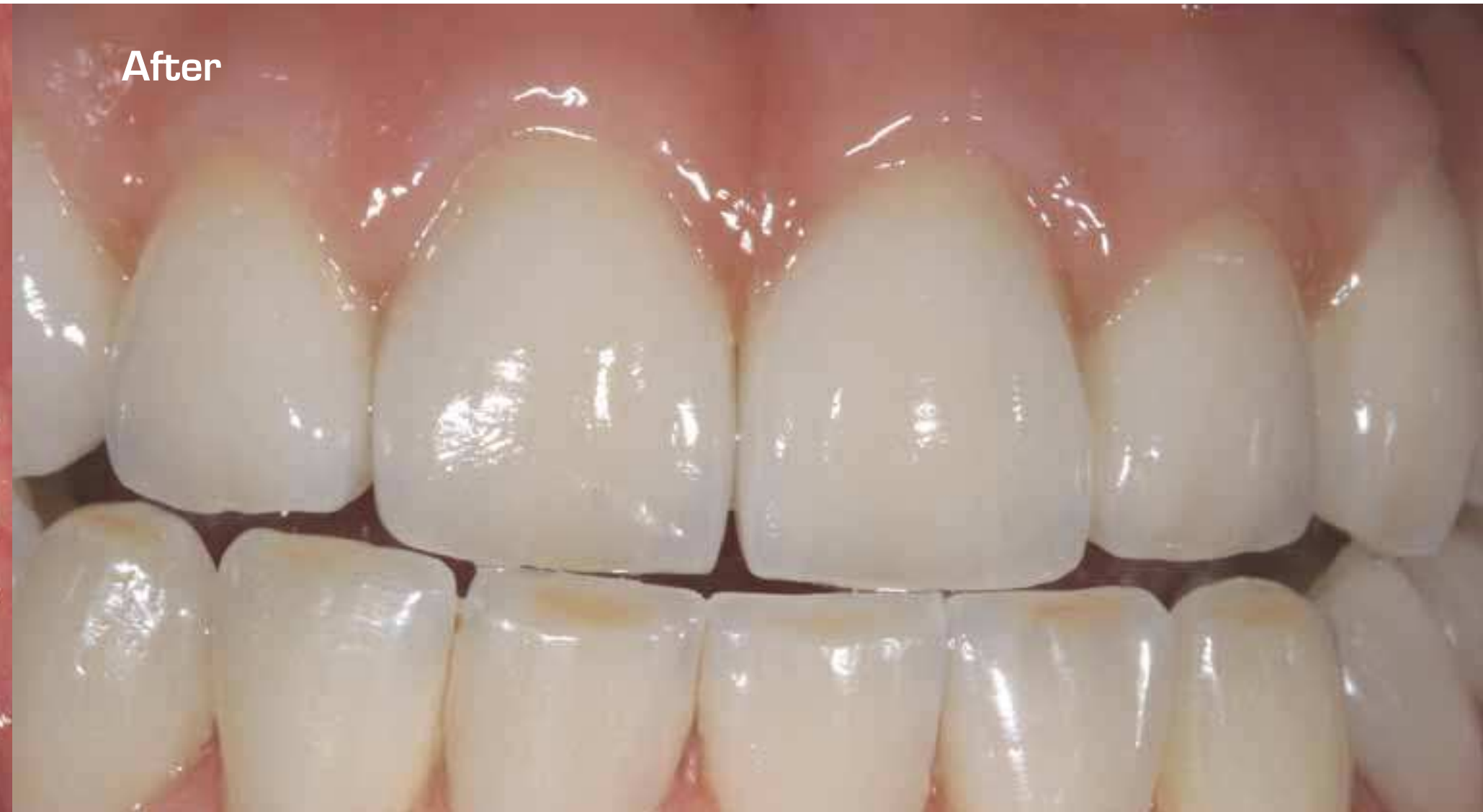Procera® Implant Bridge Zirconia  
Procera® Implant Bridge Titanium

Mr. Ernst A. Hegenbarth, Mr. Mário Alão de Almeida Vieira & Dr. Paul Chang, USA

SEVERAL TEETH OR  
ALL TEETH MISSING



After



SEVERAL TEETH OR  
ALL TEETH MISSING

Procera® Implant Bridge Zirconia  
Procera® Implant Bridge Titanium

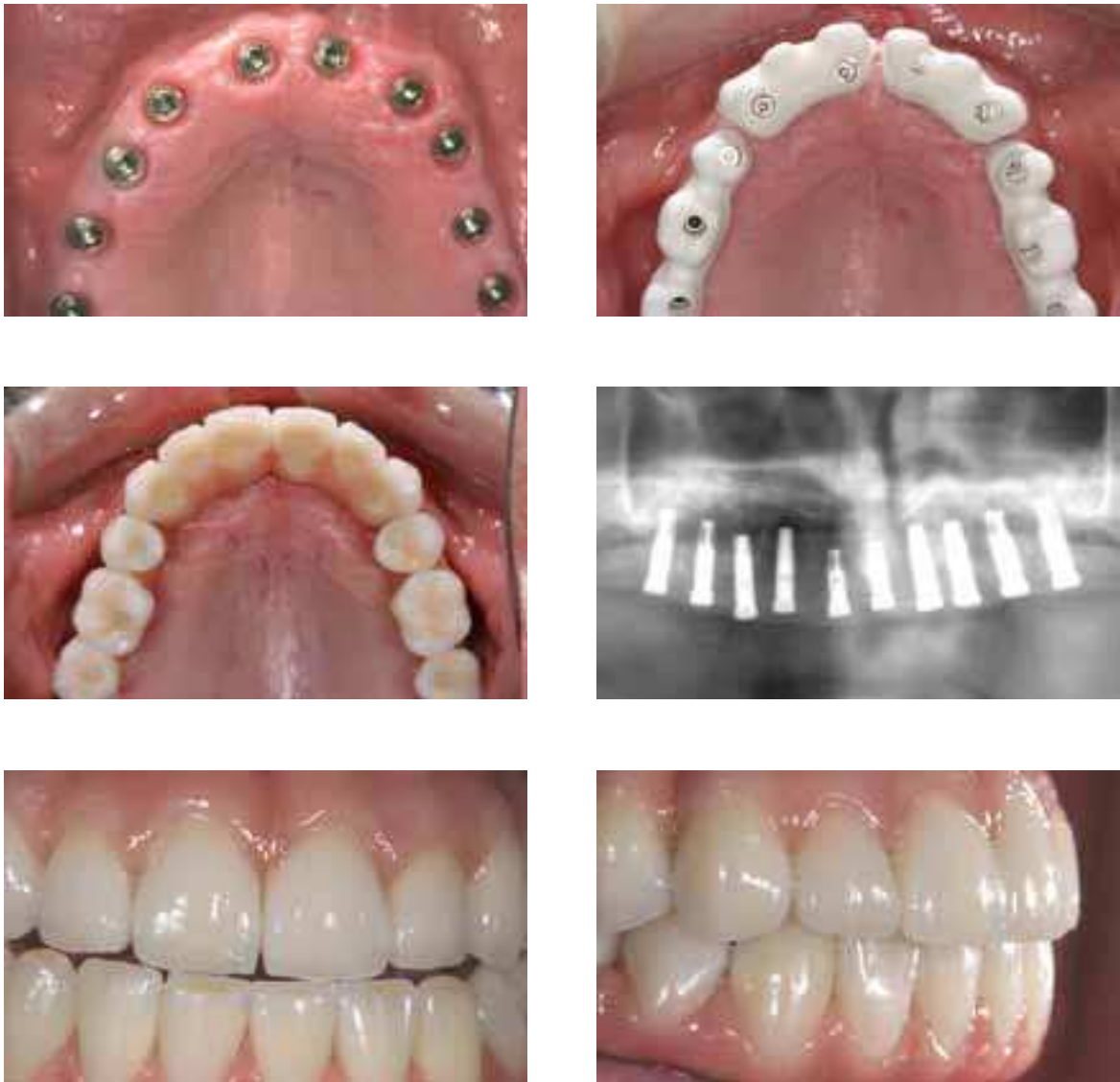
Mr. Ernst A. Hegenbarth, Mr. Mário Alão de Almeida Vieira & Dr. Paul Chang, USA

An edentulous patient was provided with five Brånemark System® implants in the mandible and ten Brånemark System® implants in the maxilla.

Two alternative treatment modalities utilizing the Procera® Implant Bridge Titanium for a retrievable prosthesis in the lower jaw and four retrievable screw retained Procera® Implant Bridge Zirconia in the upper jaw, were performed.

For the lower Procera® Implant Bridge Titanium, porcelain denture teeth were customized with Nobel-Rondo™ Alumina ceramics. The four upper Procera® Implant Bridge Zirconia, were veneered with Nobel-Rondo™ Zirconia ceramics and NobelRondo™ Gingiva Ceramics.

The patient was very satisfied with both the functional and esthetical result. With this new treatment option, also very high demands regarding esthetics, longevity and a natural look can be fulfilled. Aspects of hygiene, maintenance and even cost-effectiveness are taken into account with this solution.



SEVERAL TEETH OR  
ALL TEETH MISSING



## The great leap forward

"I first started as a practising dentist in the 1960s. To me, it was in many ways shocking to realize that so much of dental treatment seemed to have remained since the previous century.

I have the greatest respect for experience and careful development, but from the very beginning I was convinced that any dentist could gain and improve radically from new technology.

The most old-fashioned thinking was related to materials. The use of mercury in the human body is one example, which to me is just as absurd as it sounds.

A break-through like Per-Ingvar Brånemark's on osseointegration made

it very clear that modern technology could open up whole new fields of possibilities. The discovery of genuinely biocompatible materials made it possible to anchor false teeth for life. And when we later learned how to use modern ceramic materials for crowns and bridges, we could offer trouble-free every-day life for a very long time.

Using ceramics is easy. It can be introduced in most existing clinical procedures – with implants, or as traditional crowns and laminates. And it's easy also for the patient. Ceramics present excellent soft-tissue integration characteristics."

Matts Andersson, inventor of the Procera® system.





"It's tempting, and in many ways fascinating, to focus on the technical solutions of Procera®. The 3-D scanners, the advanced computing and the high-precision milling are really state-of-the-art technology.

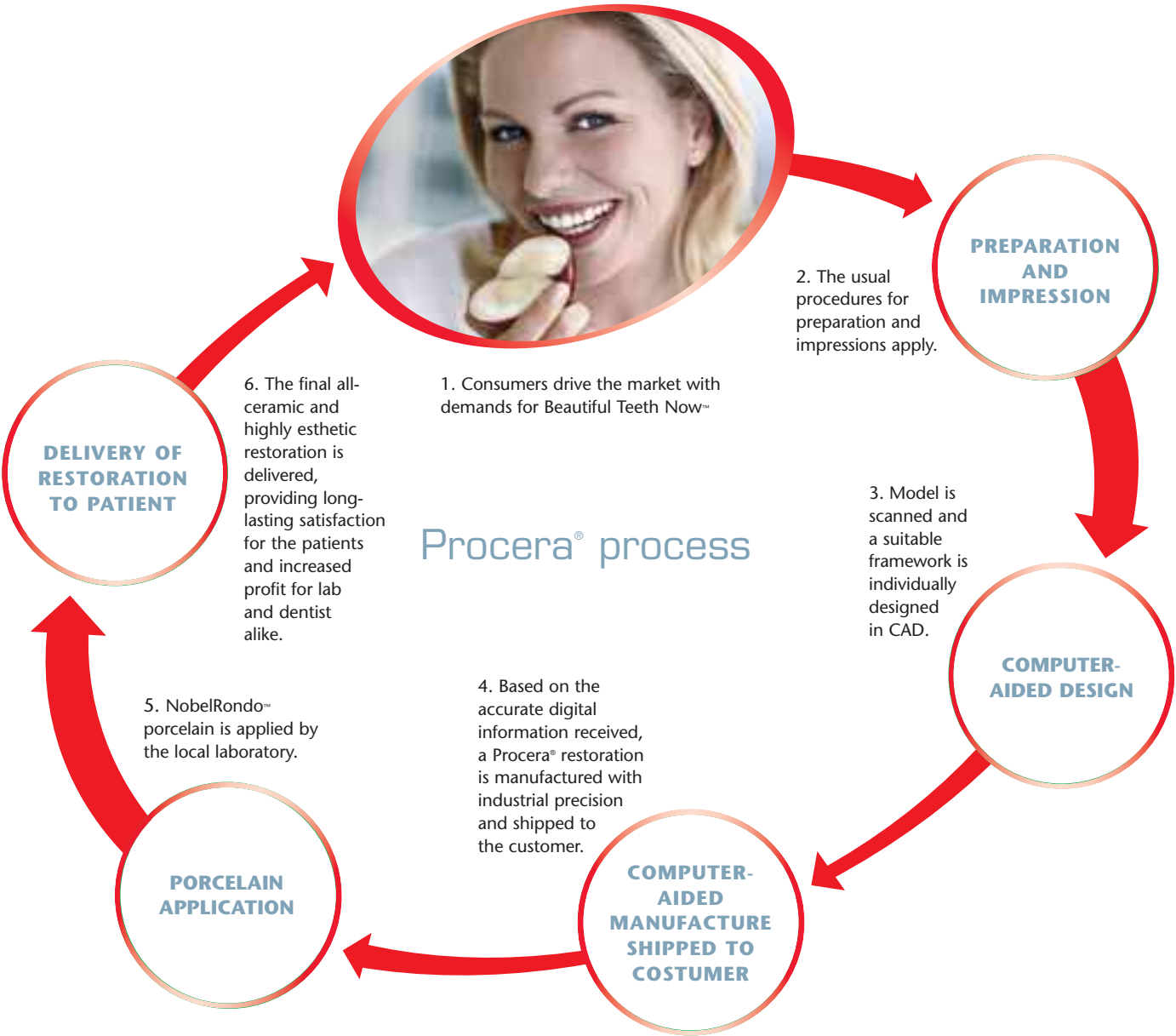But we must never forget that tools are tools. A violinmaker treasures his chisels and planes, but his expertise is closer to music than to mechanics. In the same way a dentist is more concerned about humans than about computers. And that's part of the reason why we avoid too many automated processes in the Procera® production process. The tools are there to help us, not to replace us.

As well, the entire process of dental treatment is a key factor. By minimizing the surgery, and the time the patient needs to be in treatment, we've proven that it all can be done so much simpler – for the patient and for the dentist.

My first sketches of the Procera® method looked more like a technical system design or a logistics scheme. Helping the patient is a process that can be described in three logical steps: we gather the information we need, we decide on method and we produce, for example, a crown or a bridge. And this is what's really important, to optimize each step so that the specialist can get the best information possible and present clear alternatives to the patient.

Modern advancement in networking lets us help dentists and laboratories anywhere in the world. Using the internet, an open architecture, makes it easy to enter the world of Procera® and to offer safe and rapid treatment to new patient groups."

Matts Andersson  
DDS, PhD





Courtesy of Dr. Mauro Fradeani, Italy